



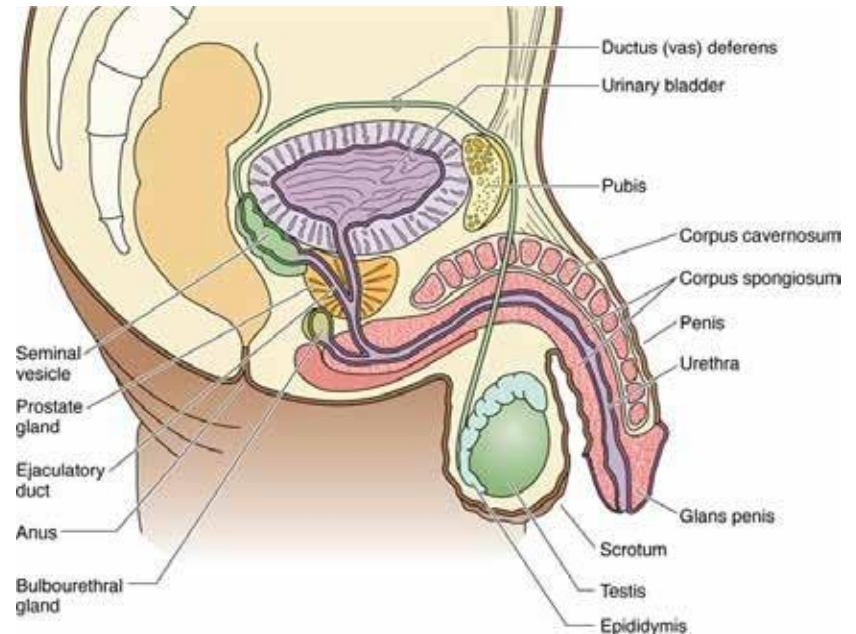
University of Kragujevac
Faculty of Medical Sciences
Integrated academic studies of pharmacy
Department of Histology and Embryology

REPRODUCTIVE SYSTEM, URINARY SYSTEM

Male reproductive system

Male reproductive system

- The male reproductive system consists of:
- Gonads or a pair of testicles, whose function is the creation of spermatozoa and the synthesis of androgenic hormones;
- A paired system of excretory ducts that collect and conduct spermatozoa;
- Auxiliary exocrine glands, which produce seminal fluid, as well as fluid that moistens the urethra;
- Penis, copulatory organ.



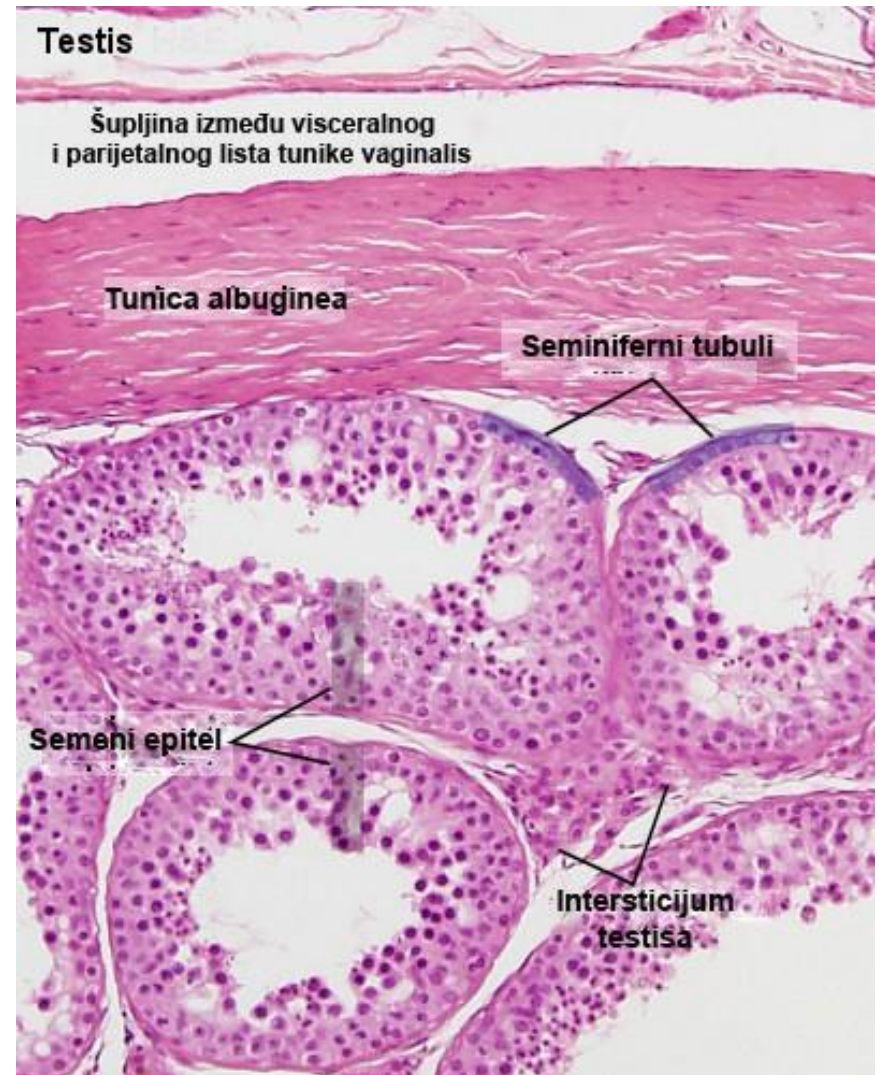
Gartner and Hiatt: Color Textbook of Histology, 3rd ed. Philadelphia, W.B. Saunders, 2007.

Testicle

- The testicles are paired organs that develop in the abdomen during embryogenesis, and later descend into the scrotum during fetal life.
- The scrotum is covered with skin with numerous hair follicles and sweat glands.
- In the deeper layers of the skin of the scrotum, there are muscle fibers that, with their contractions, enable the mobility of the skin of the scrotum.

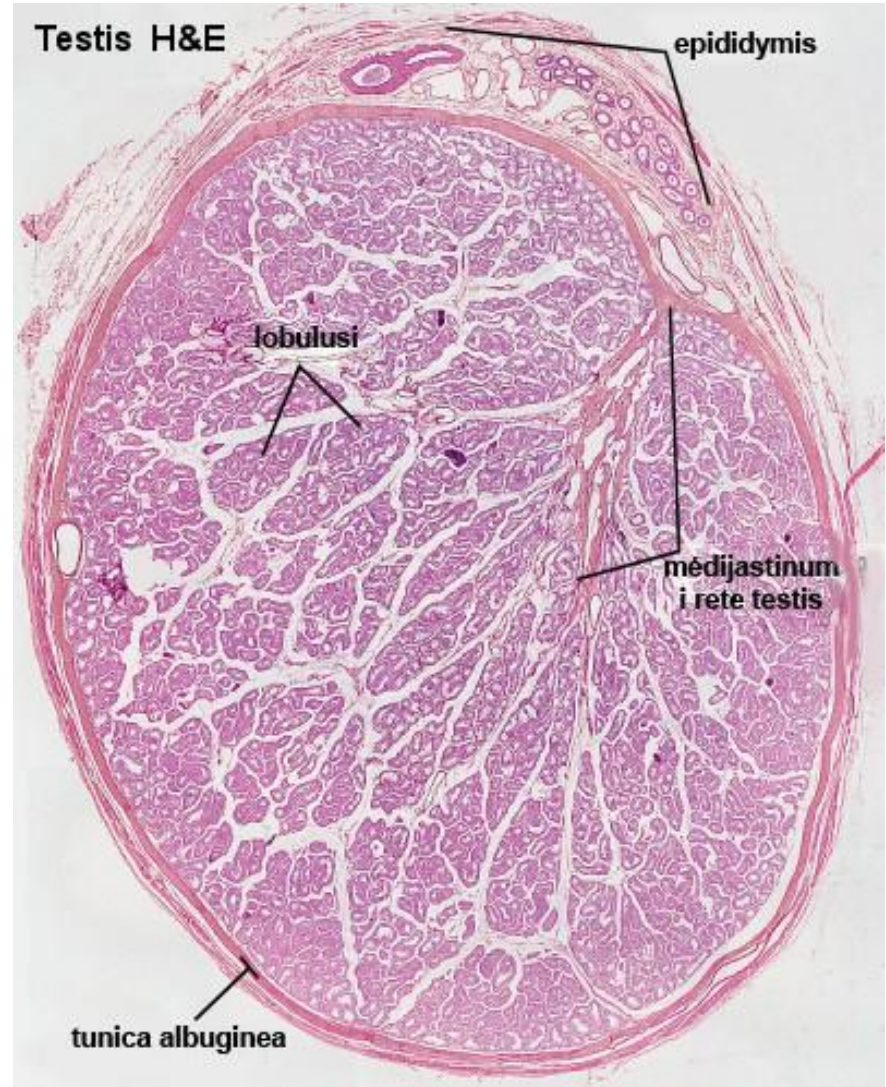
Testicle

- The surface of the testis is covered by the tunica vaginalis, which has a parietal and a visceral sheet, between which there is a small amount of fluid that prevents friction.
- The parietal sheet is lined with mesothelium, while the visceral sheet around the testis forms a capsule called the tunica albuginea (tunica albuginea).



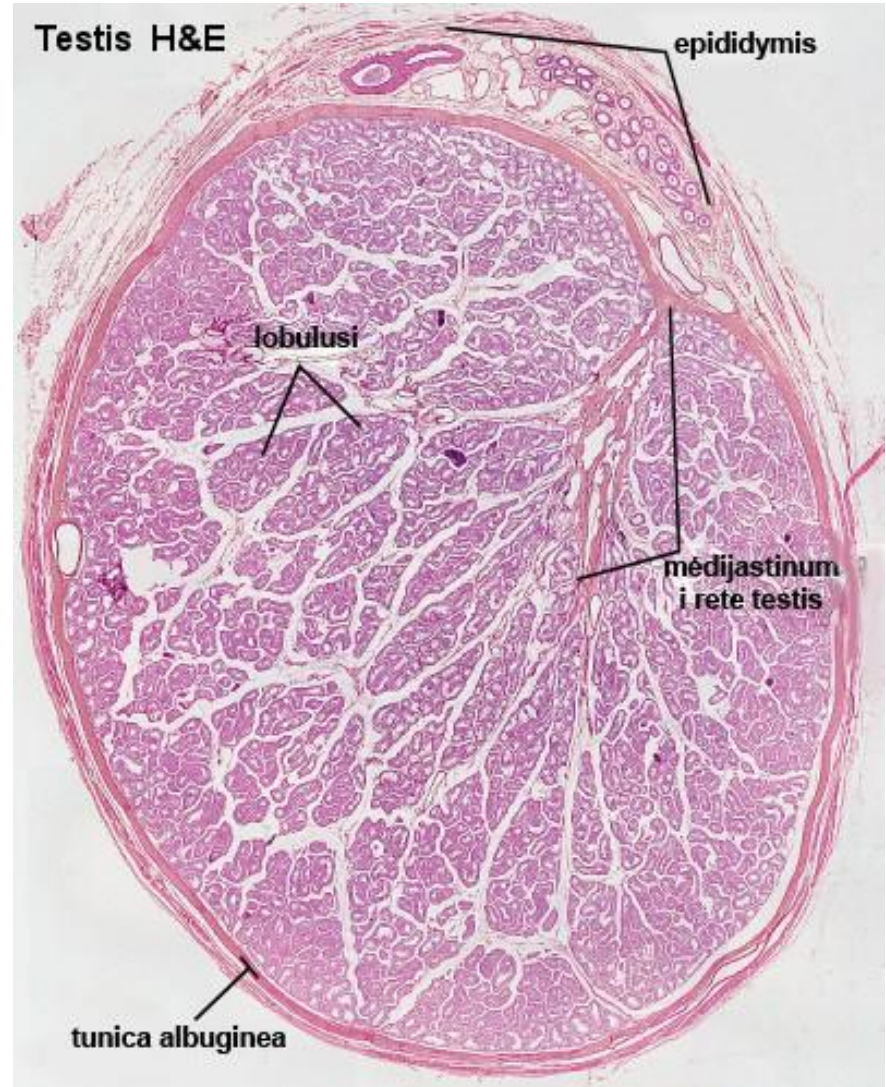
Testicle

- This connective capsule is thickened in its posterior part where it forms the testicular mediastinum.
- Blood vessels and connective septa depart from the mediastinum, which incompletely divide the interstitium of the testis into about 250 lobes (lobuli testis).



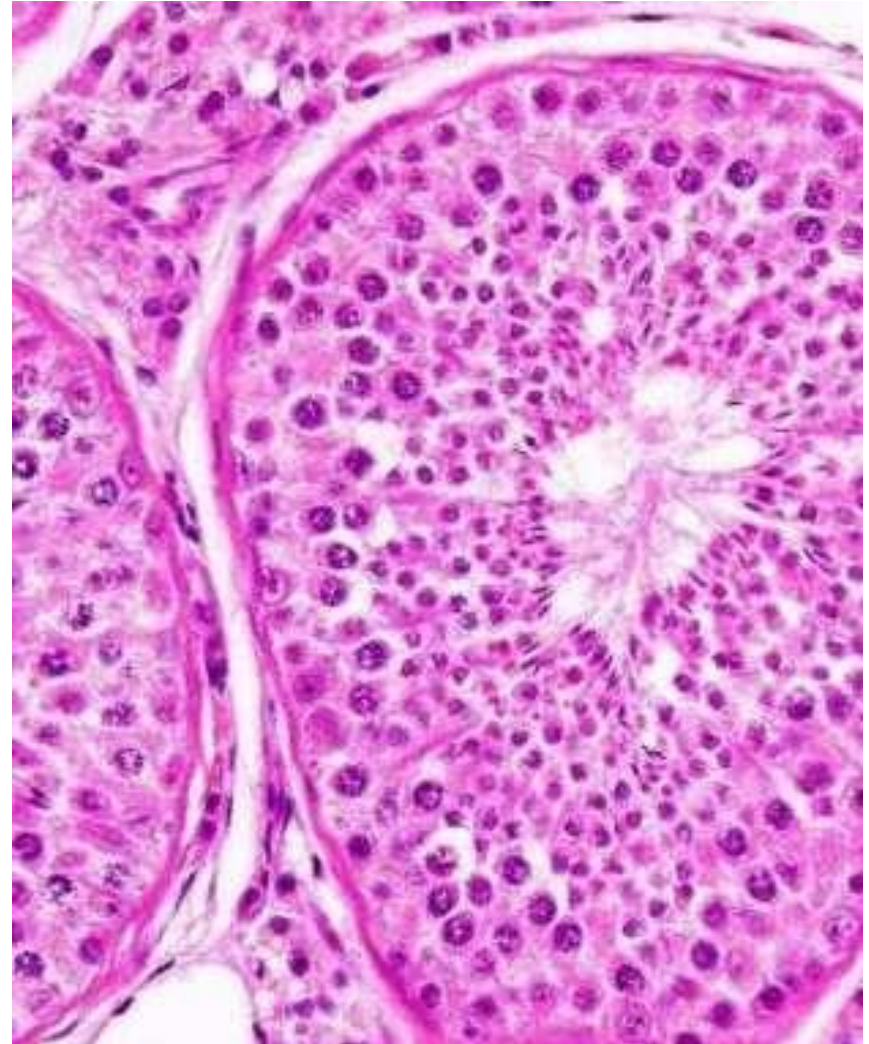Testicle

- In each lobule of the testis there are 1-4 very twisted ducts called seminiferous tubules or seminiferous tubules (tubuli seminiferi contorti).
- Spermatogenesis takes place in the seminiferous tubules of the testes.



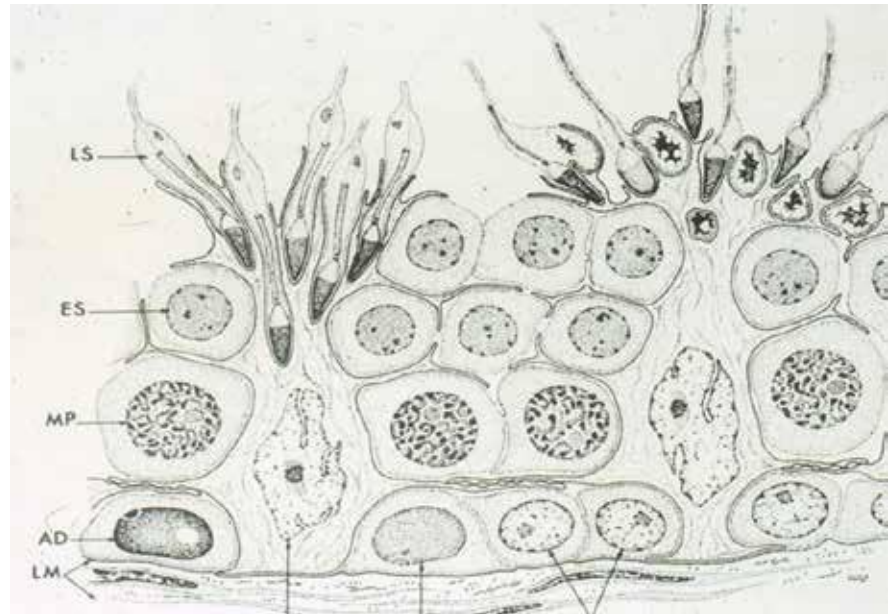
Seminiferous tubules

- The seminiferous tubules are lined with a specific stratified epithelium called the seminiferous (germinal) epithelium.
- This epithelium contains two distinct cell populations: spermatogenic (germinative) and Sertoli (supporting) cells.



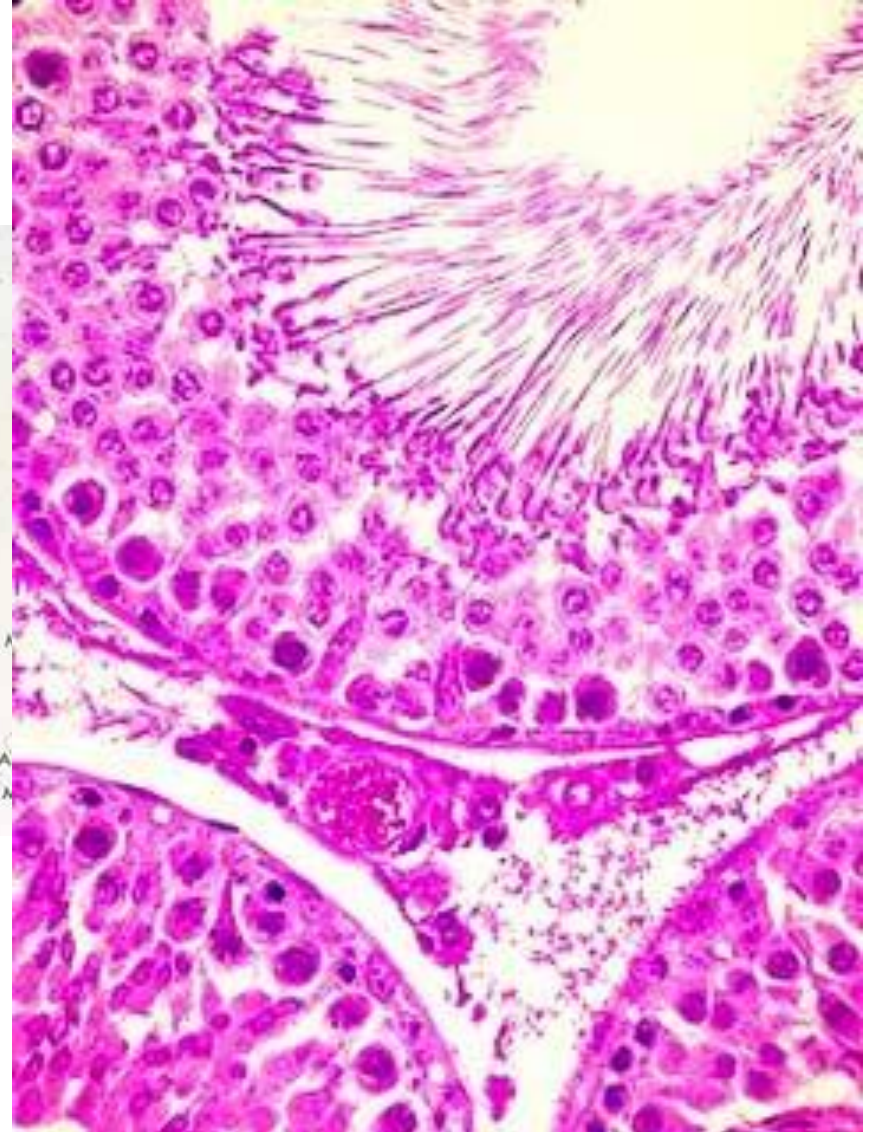
Seminiferous tubules

- Spermatogenic cells are male germ cells that divide and migrate from the basement membrane to the lumen, gradually maturing.
- These different developmental stages of spermatogenic cells make up the seminiferous epithelium.



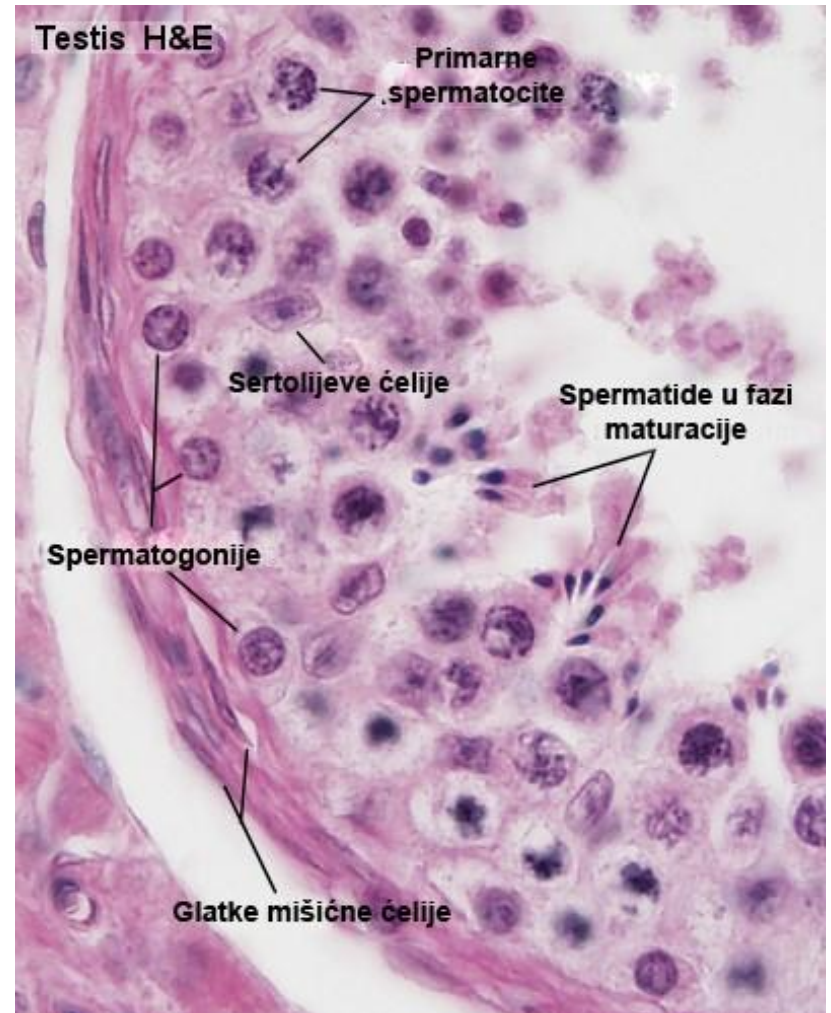
Seminiferous tubules

- **Germ cells include different cellular entities:**
- spermatogonia
- primary spermatocytes
- secondary spermatocytes
- spermatids
- spermatozoa



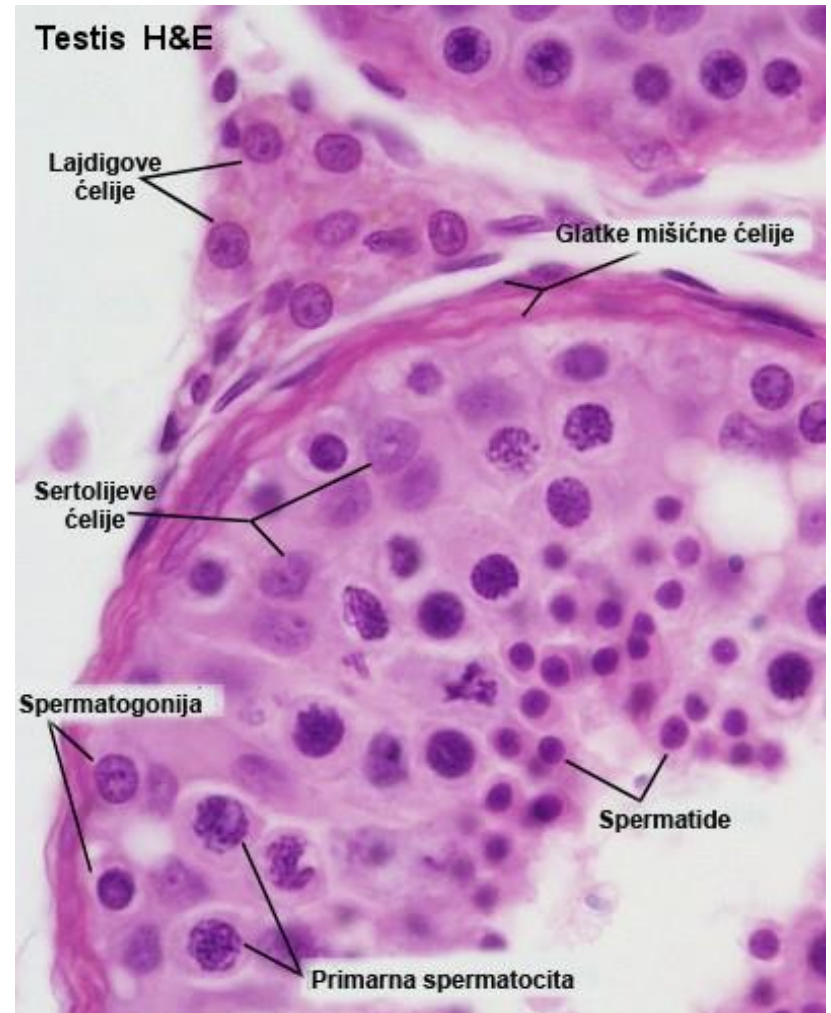
Seminiferous tubules

- Spermatogonia are located directly next to the basement membrane.
- Some spermatogonia undergo mitotic divisions to give rise to new generations of spermatogonia and remain stem cells, while others differentiate into primary spermatocytes.
- This process represents the proliferative phase of spermatogenesis.



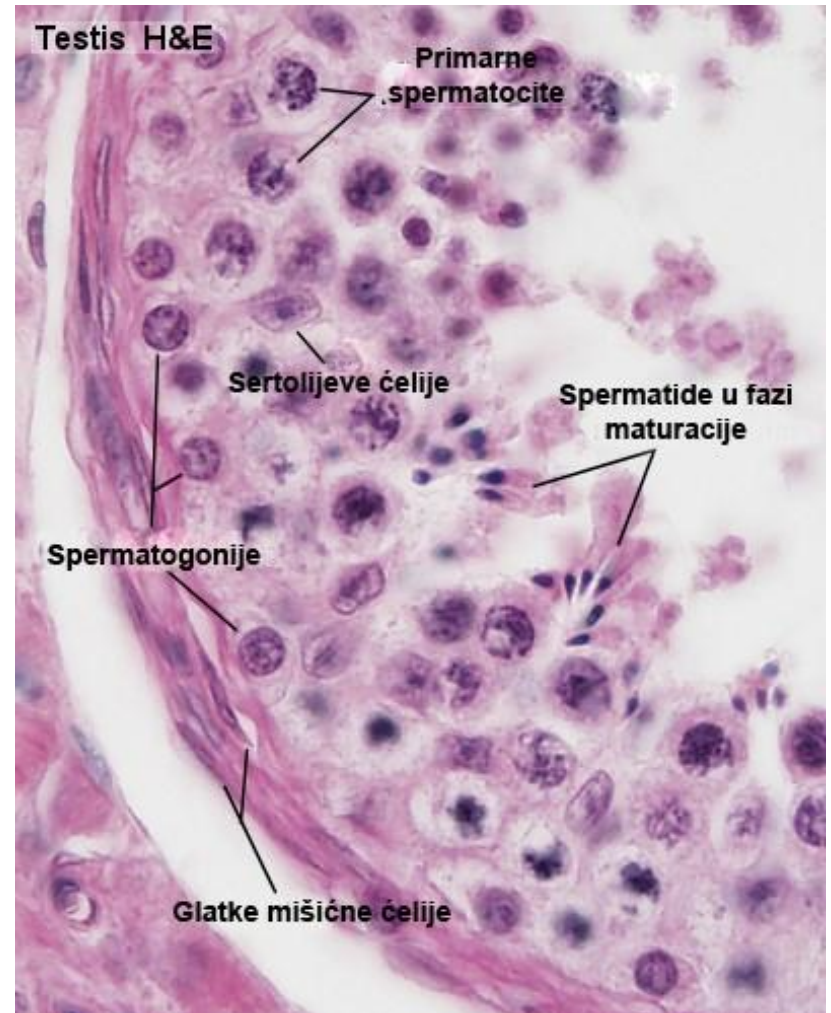
Primary and secondary spermatocytes

- Primary and secondary spermatocytes undergo meiotic divisions.
- Secondary spermatocytes are formed from primary spermatocytes by the first meiotic division.
- Spermatids are formed from secondary spermatocytes by the second meiotic division.
- This process is called the meiotic phase of spermatogenesis.



Spermatids

- Spermatids are located in the apical parts of the seminiferous epithelium.
- They differentiate into spermatozoa through the process of spermiogenesis, which represents the third phase of spermatogenesis.



Spermatogenesis

- The process of male gamete production from spermatogonia to spermatozoa.
- It starts at puberty.
- Cells of spermatogenesis:
 - Spermatogonia A and B - diploid cells (46 chromosomes)
 - Primary spermatocytes – diploid cells (46 chromosomes)
 - Secondary spermatocytes – haploid cells (23 chromosomes)
 - Spermatids – haploid cells (23 chromosomes)
 - Sperm - haploid cell (23 chromosomes)

Spermatogenesis

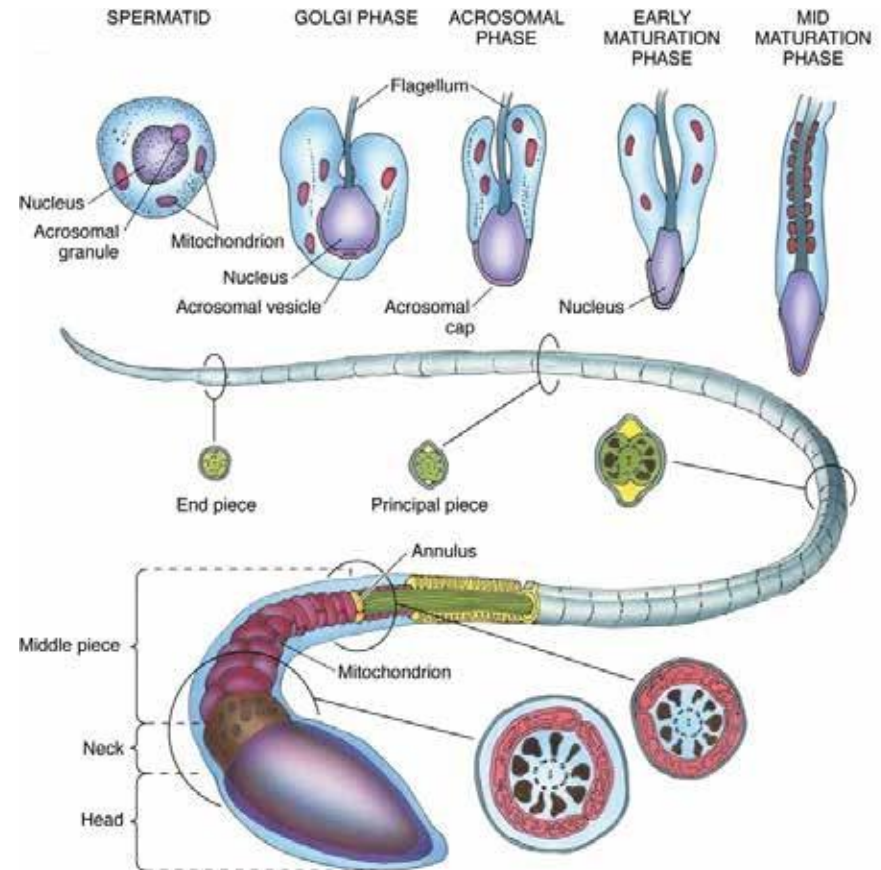
- It represents the differentiation of spermatid into sperm.
- The process of spermiogenesis is characterized by:
- Acrosome formation
- Extending the tail
- Chromatin condensation (transcriptionally inactive)
- Growth of flagella from centrioles
- Loss of spermatid cytoplasm (residual bodies)

Spermatozoa

In the process of spermiogenesis, spermatids shed most of their cytoplasm and create flagella, transforming into spermatozoa.

A spermatozoon is a long cell (~65 μm), which is composed of a head, which contains the nucleus and tail responsible for its length.

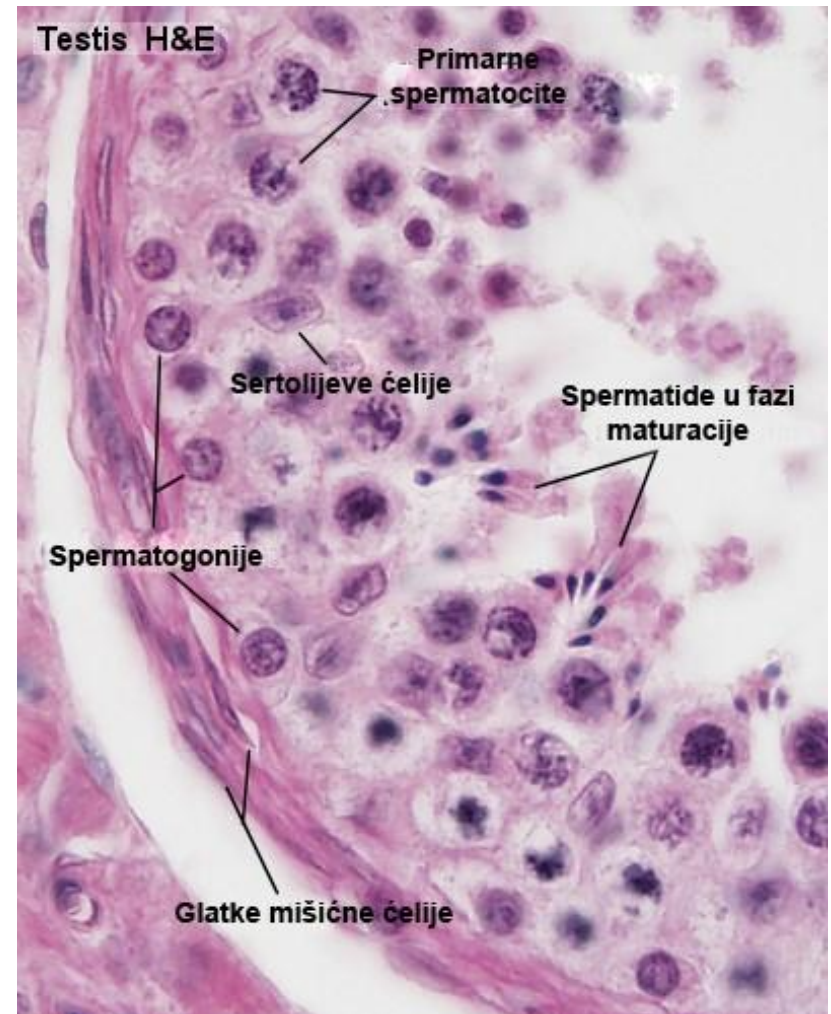
The sperm tail consists of: the neck, the middle, the main and the final part.



Gartner and Hiatt: Color Textbook of Histology, 3rd ed.
Philadelphia, W.B. Saunders, 2007.

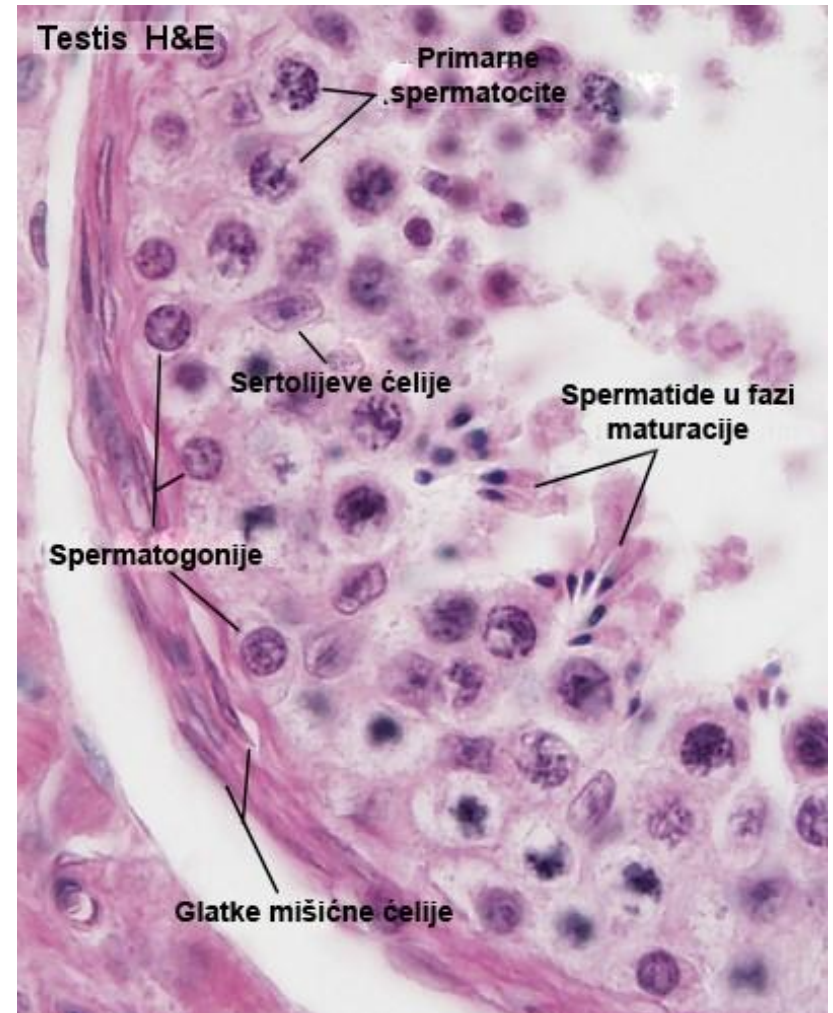
Sertoli cells

- Sertoli cells are the supporting cells of the seminiferous epithelium.
- Each Sertoli cell passes through the entire thickness of the seminiferous epithelium.
- They are polarized cylindrical cells with an apical, lateral and basal compartment.



Sertoli cells

- Spermatogenic cells are located in the recesses of the cell membrane of Sertoli cells.
- Sertoli cells do not migrate or divide.
- There is a structural and functional interdependence between Sertoli cells and germ cells.

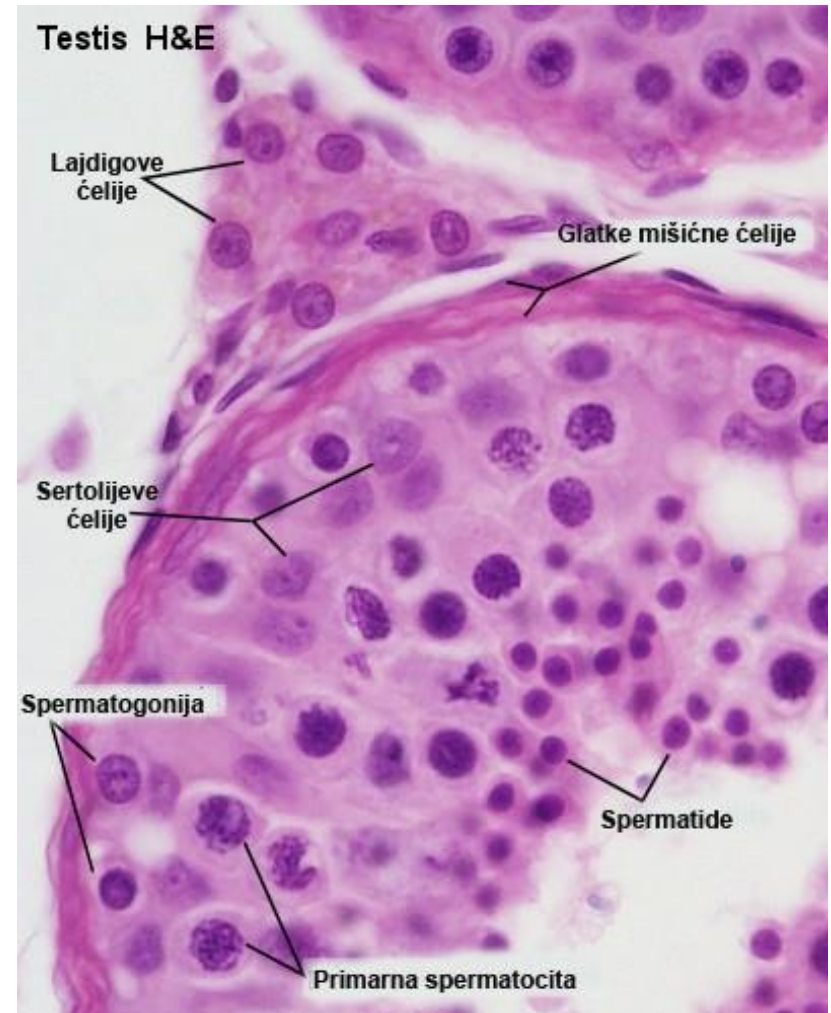


Sertoli cells

- Sertoli cells have multiple roles:
- Formation of the blood-testis barrier;
- Supportive-nutritive function - they support the development of germ cells;
- Phagocytic role - they perform phagocytosis of the residual cytoplasm of spermatids and remove degenerated spermatozoa;
- Secretory role - produce androgen-binding protein, anti-Müllerian hormone, inhibin, transferrin and medium rich in fructose.

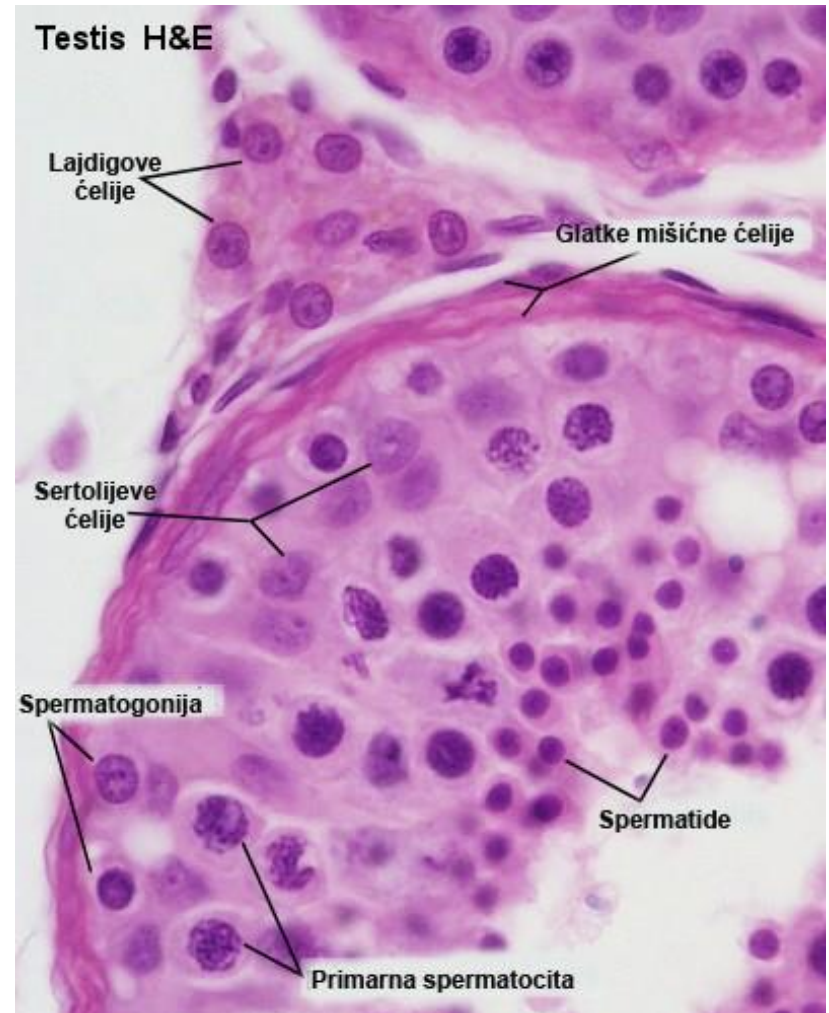
Testicular interstitial tissue

- The loose connective tissue around the seminiferous tubules contains:
- endocrine Leydig's cells
- blood and lymphatic vessels
- nerve fibers
- fibroblasts, macrophages and mast cells.



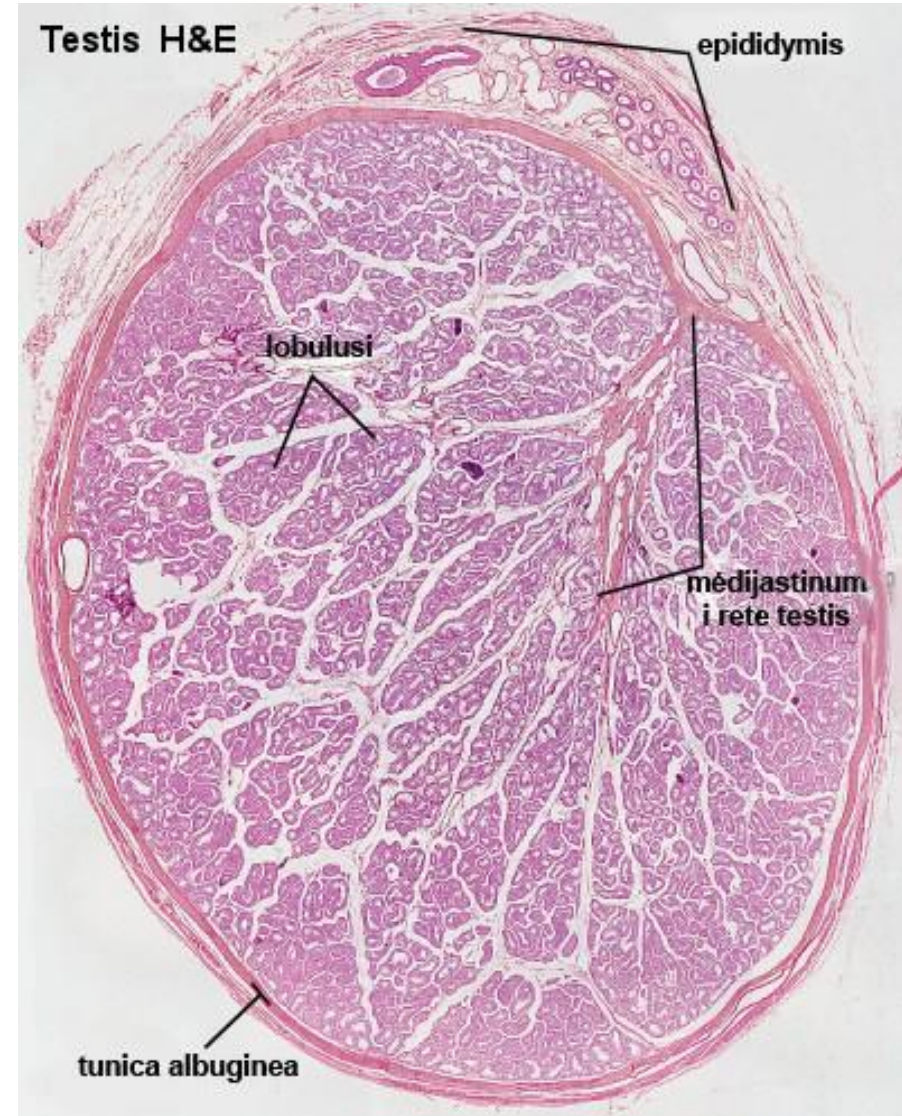
Leydig cells

- Leydig cells are large, polygonal, acidophilic cells that secrete testosterone.
- They have the characteristics of cells that produce steroid hormones: a large amount of glER, mitochondria with tubulovesicular cristae, fat droplets and a highly developed Golgi complex.



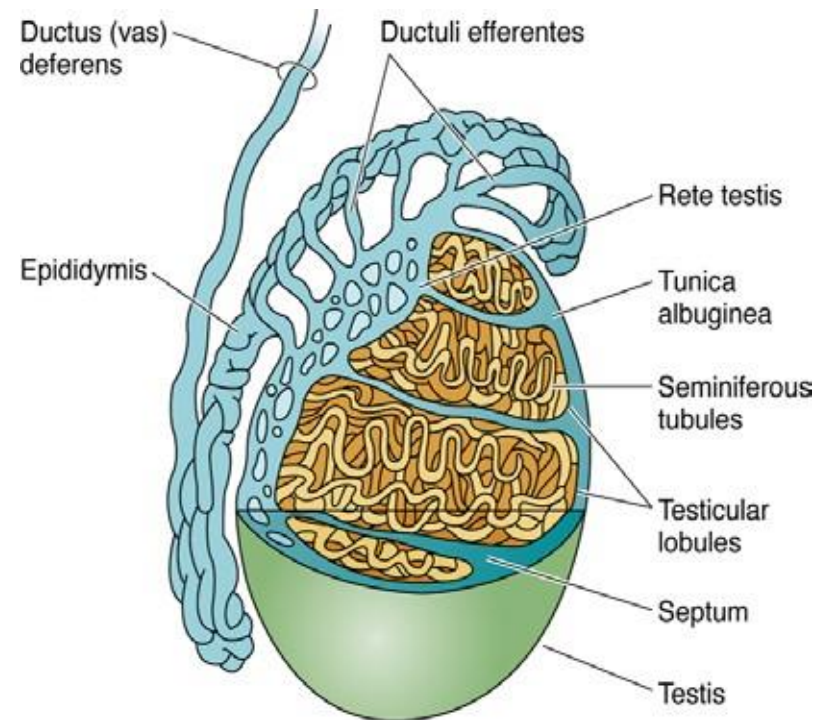
Intratesticular ducts

- The formed spermatozoa from the convoluted seminiferous tubules pass into their true parts of the rectal tubule (containing only Sertoli cells).
- The rectal tubules then join in the mediastinum of the testis to form the rete testis.
- The tubules in the rete testis are lined with a single row of squamous epithelium.
- Further joining of rete testis ducts creates 10-20 draining ducts (ductuli efferentes) that pass through the tunica albuginea and form the head of the epididymis.



Extratesticular ducts

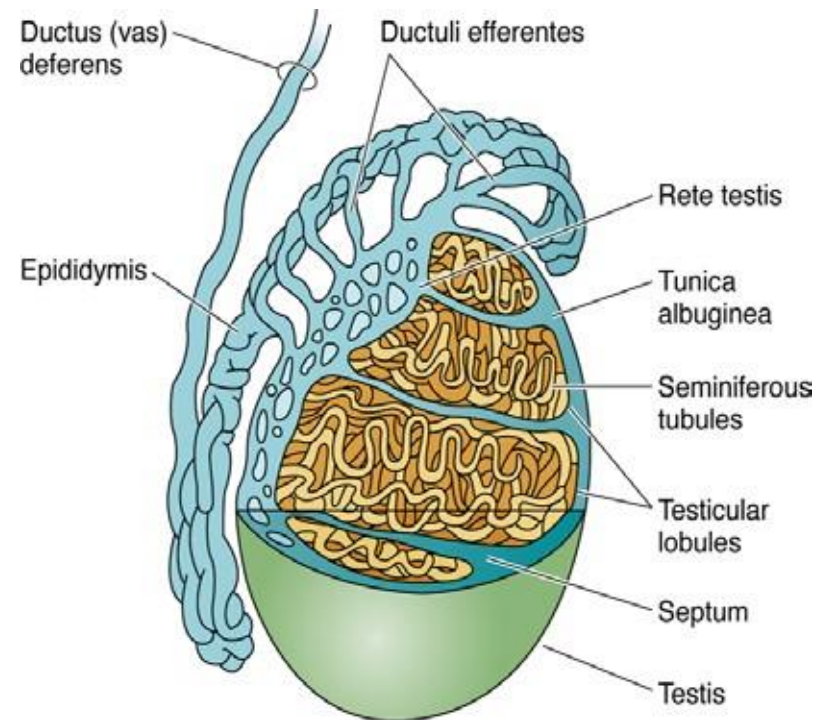
- The ductuli efferentes form the initial part of the extratesticular excretory ducts.
- Three layers can be recognized in their wall:
 - tunica mucosa
 - tunica muscularis
 - tunica adventitia
- Mucous membranes are included in the composition of the tunic
- epithelium and lamina propria.
- In the initial part, the epithelium is simple cuboidal, and then it is replaced by a pseudostratified double-layered epithelium.



Gartner and Hiatt: Color Textbook of Histology, 3rd ed. Philadelphia, W.B. Saunders, 2007.

Ductus epididymis

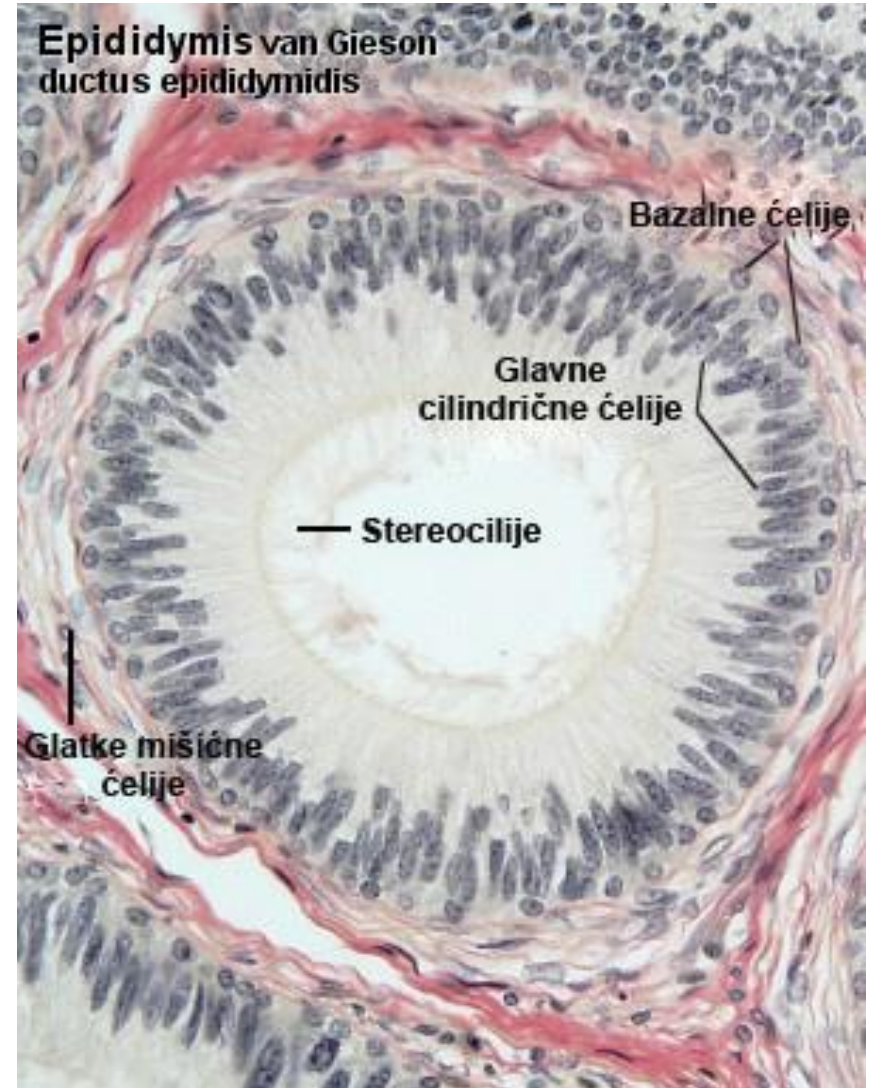
- The joining of ductuli efferentes creates the initial segment or head of the epididymis (caput epididymis).
- The central, thinner part of this tubular organ continues to the head of the epididymis - the body (corpus).
- The final segment is the tail (cauda epididymis).



Gartner and Hiatt: Color Textbook of Histology, 3rd ed. Philadelphia, W.B. Saunders, 2007.

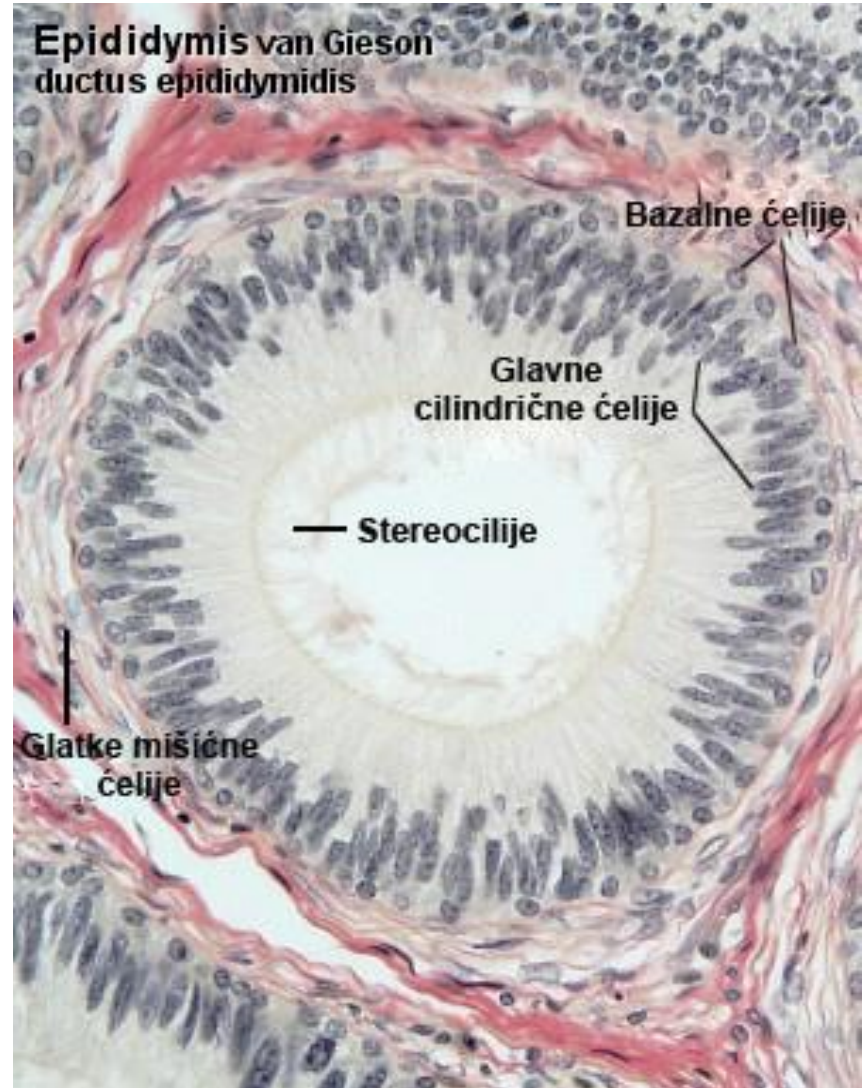
Ductus epididymis

- The wall of the epididymis consists of three layers:
- tunica mucosa
- tunica muscularis
- tunica adventitia



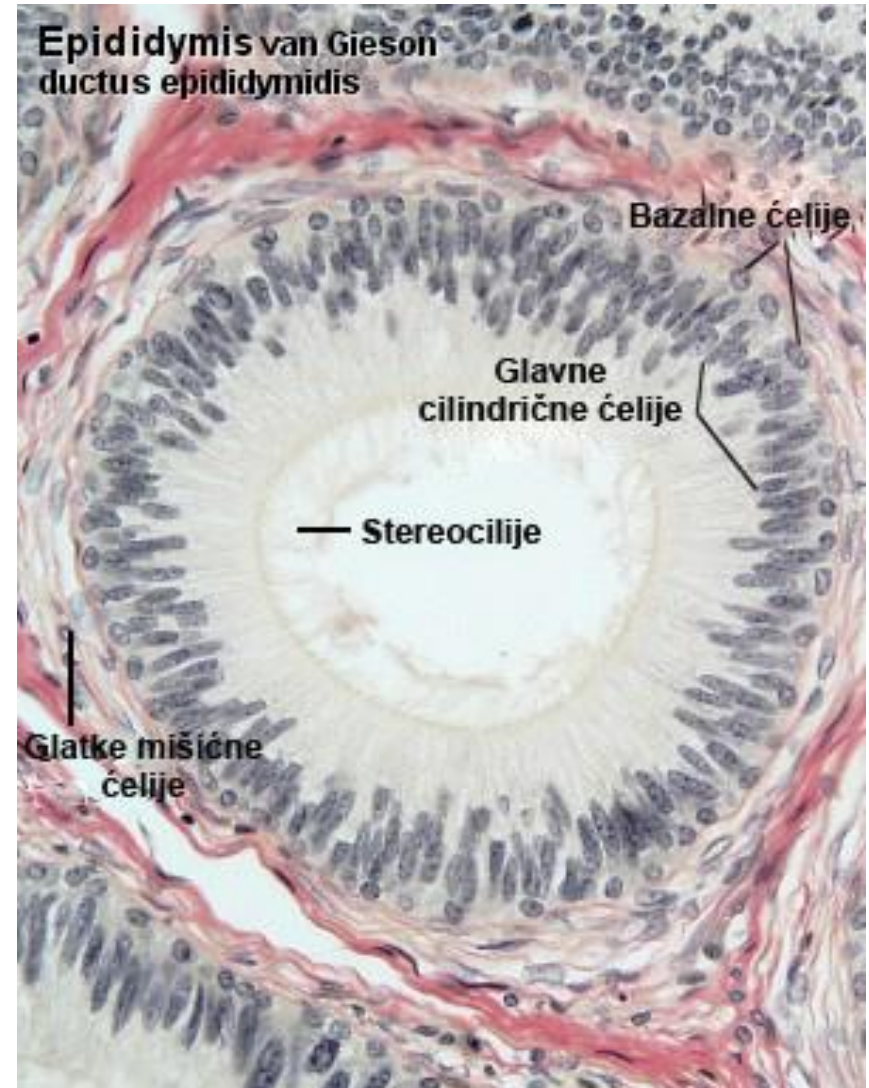
Ductus epididymis

- The tunica mucosa consists of lamina epithelialis and lamina propria.
- It builds the lamina epithelialis
- pseudostratified bilayered epithelium.
- In the composition of the epithelium there are tall cylindrical cells with long microvilli and low basal stem cells.
- The lamina propria is made up of rare fibroblasts and collagen fibrils.



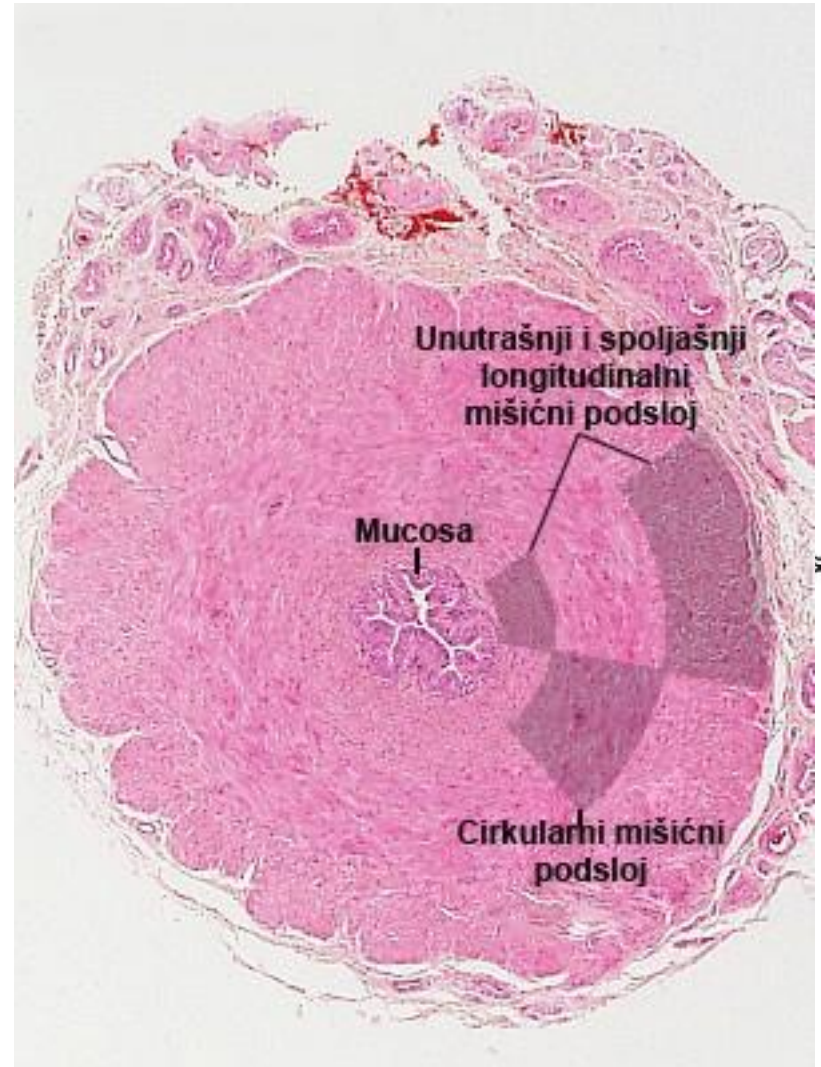
Ductus epididymis

- The tunica muscularis is composed of one circular layer of smooth myocytes in the initial parts, while in the tail area it is significantly thicker and three-layered.
- On the surface of the epididymis there is richly vascularized loose connective tissue (tunica adventitia) that forms a thin fibrous capsule.



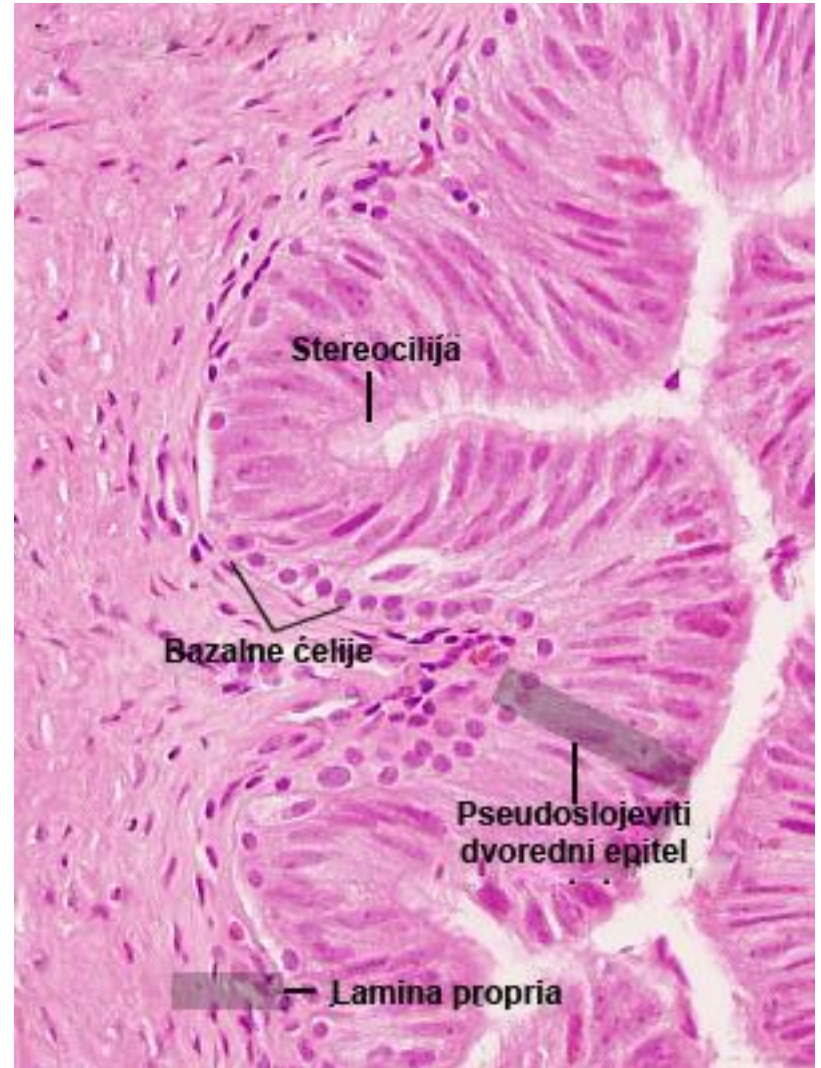
Ductus seu vas deferens

- Starting from the tail of the epididymis, the drainage canal system continues with the ductus deferens.
- During ejaculation, the ductus deferens allows sperm to be discharged into the urethra.
- The wall of this tubular organ also consists of three layers: tunica mucosa, tunica muscularis and tunica adventitia.



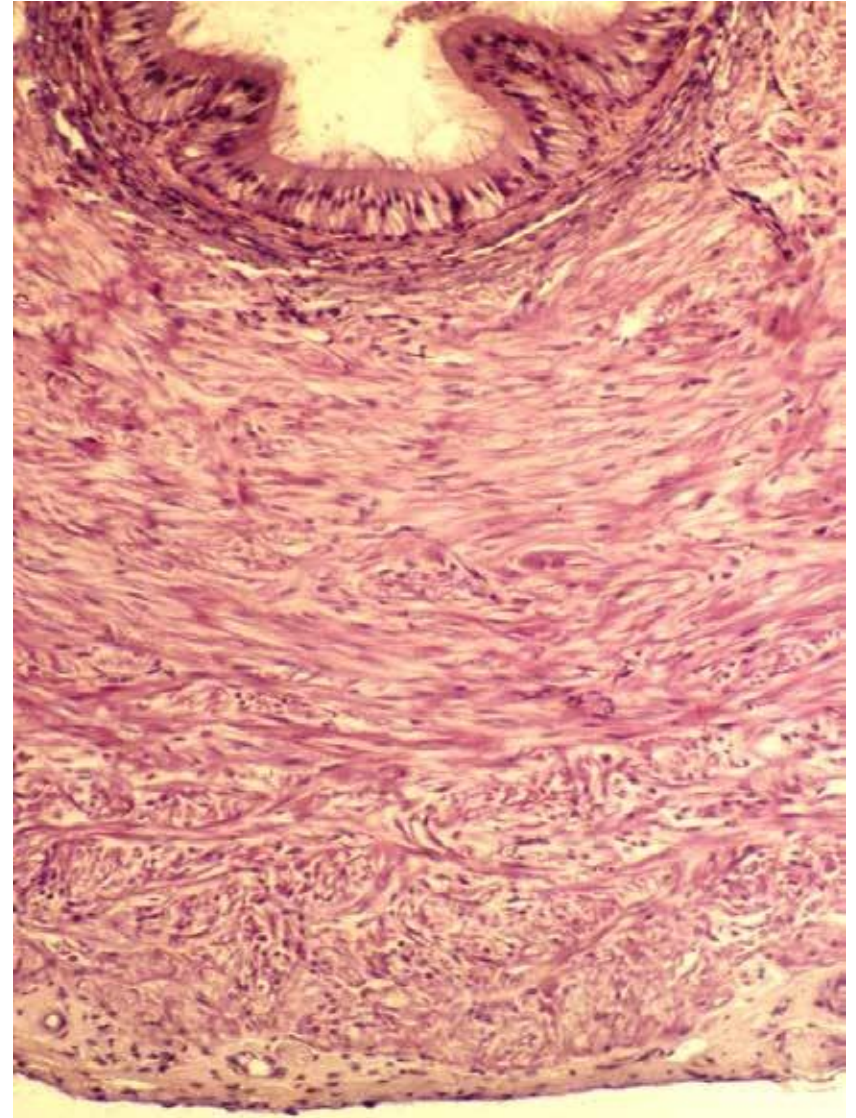
Ductus deferens

- The tunica mucosa consists of epithelium and lamina propria.
- Pseudostratified bilayered epithelium contains tall cylindrical cells with stereocilia and low basal, stem cells.
- The lamina propria is rich in elastic fibers



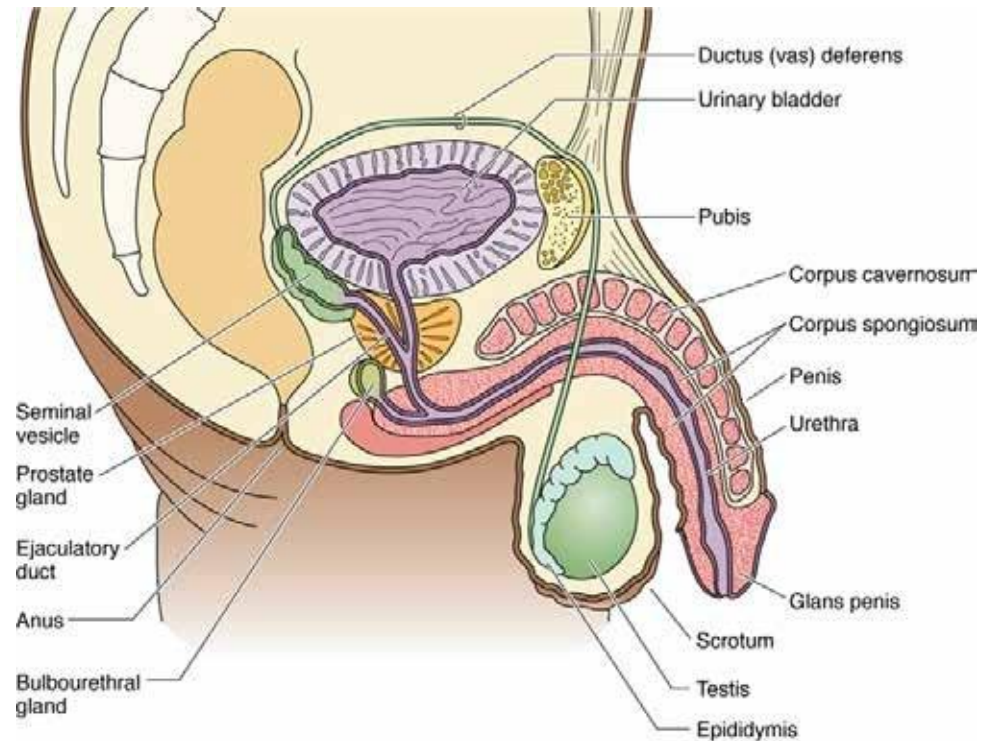
Ductus deferens

- The most developed part of the wall of the ductus deferens is the tunica muscularis.
- It consists of three layers: outer and inner longitudinal and middle thick circular layer.
- On the surface of the vas deferens there is a layer of loose connective tissue - the tunica adventitia.



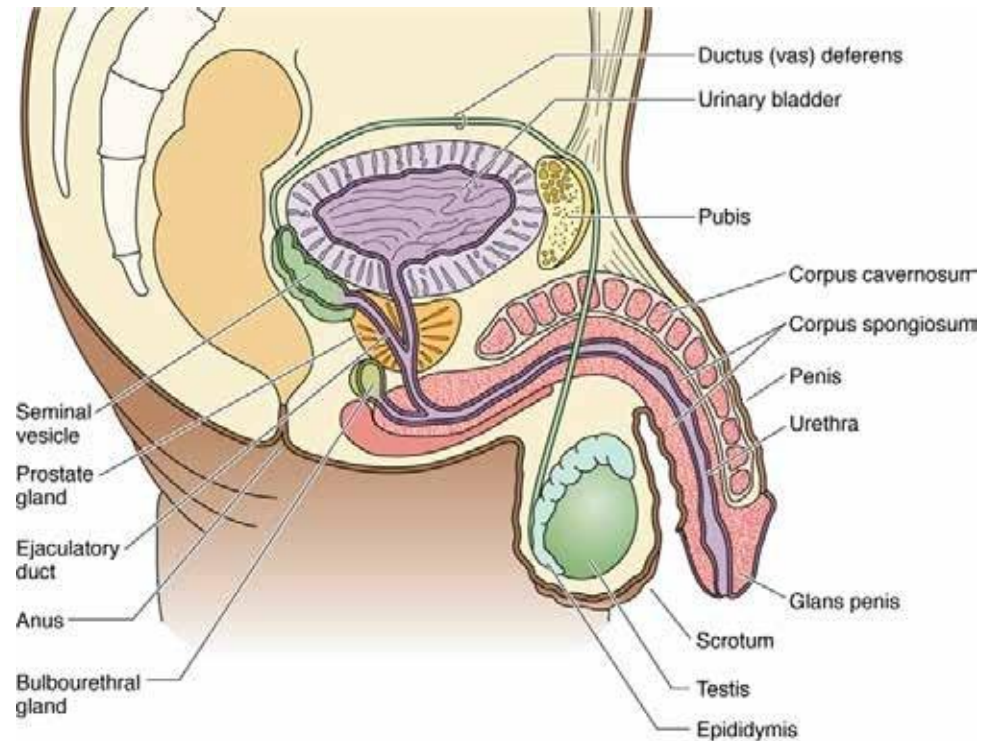
Ductus deferens

- In its final part, the ductus deferens expands, building an ampulla (ampulla ducti deferenti), into which the exit ducts of the seminal vesicles flow at the moment when spermatozoa pass through the ampulla.
- At the end of the ampullary expansion, the ductus deferens enters the body of the prostate and in that segment its wall loses the tunica muscularis and the adventitia.
- This final part of the seminal duct is called the ductus ejaculatorius and it ends by flowing into the lumen of the prostatic part of the urethra.



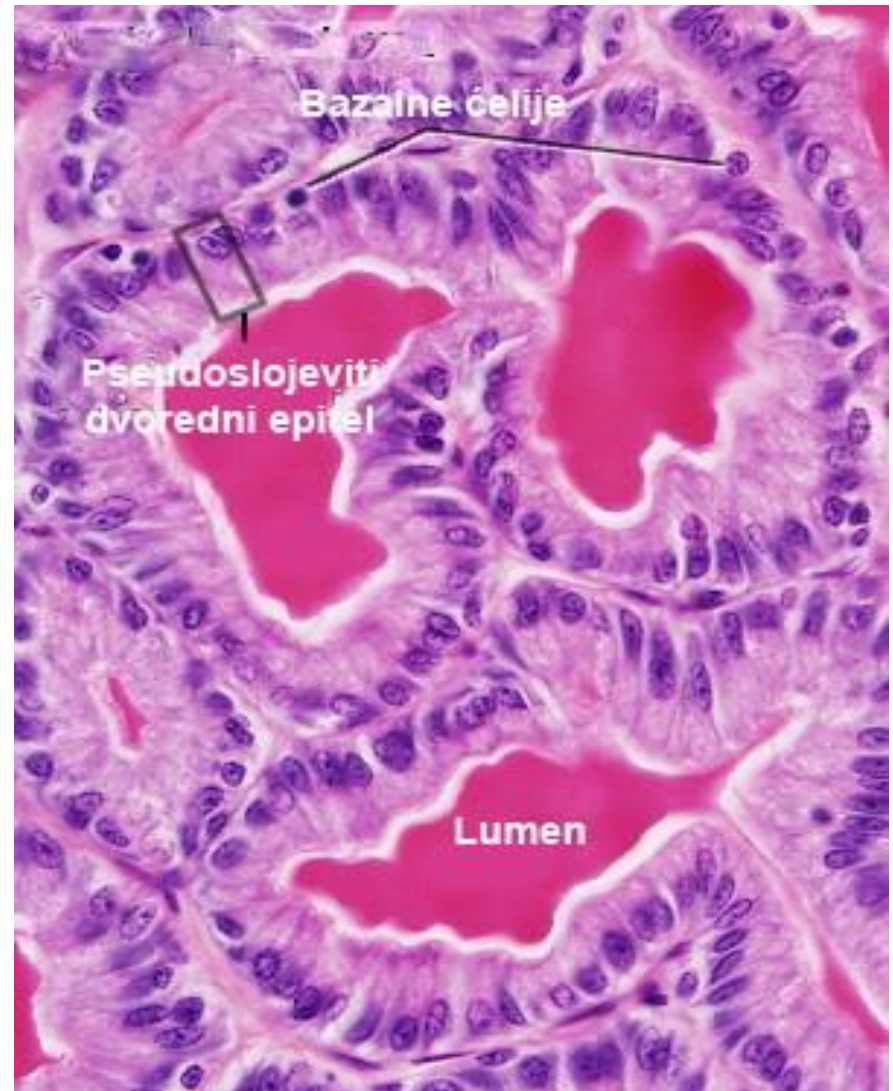
Auxiliary glands of the male reproductive system

- Glands attached to the male reproductive tract are:
- seminal vesicles
- prostate and
- Cowper's bulbourethral glands



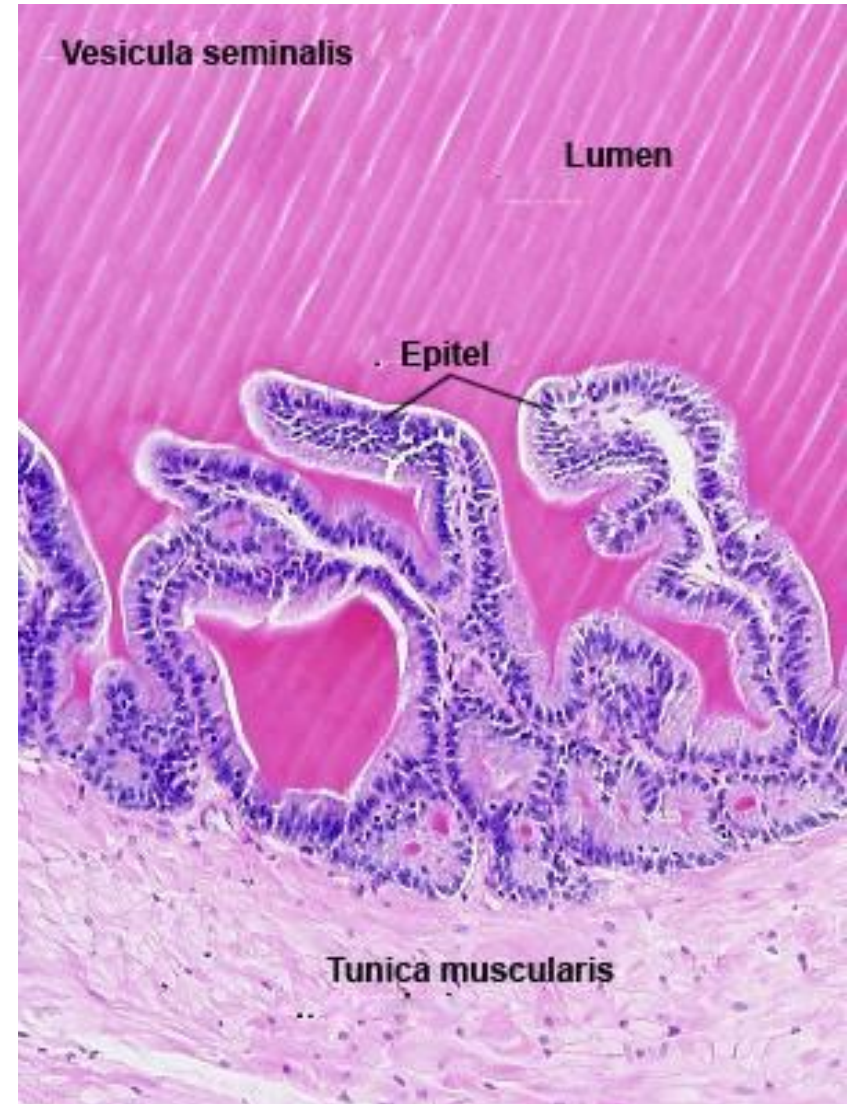
Vesicula seminalis

- The seminal vesicles are paired glands of an oblong shape, surrounded by a capsule, located along the back wall of the urinary bladder.
- Each of them is a twisted tube about 15 cm long.
- The space between the "spirals" is filled with loose connective tissue



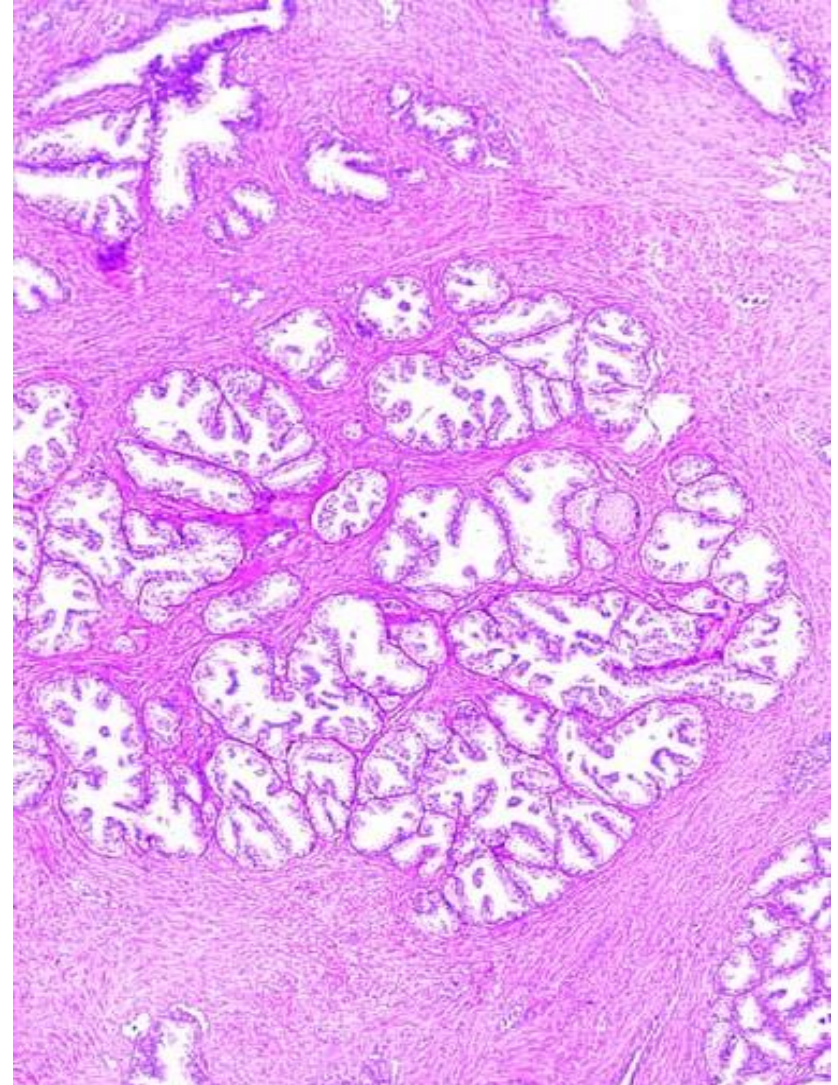
Vesicula seminalis

- The wall of the seed sac consists of three layers:
- tunica mucosa
- tunica muscularis
- tunica adventitia



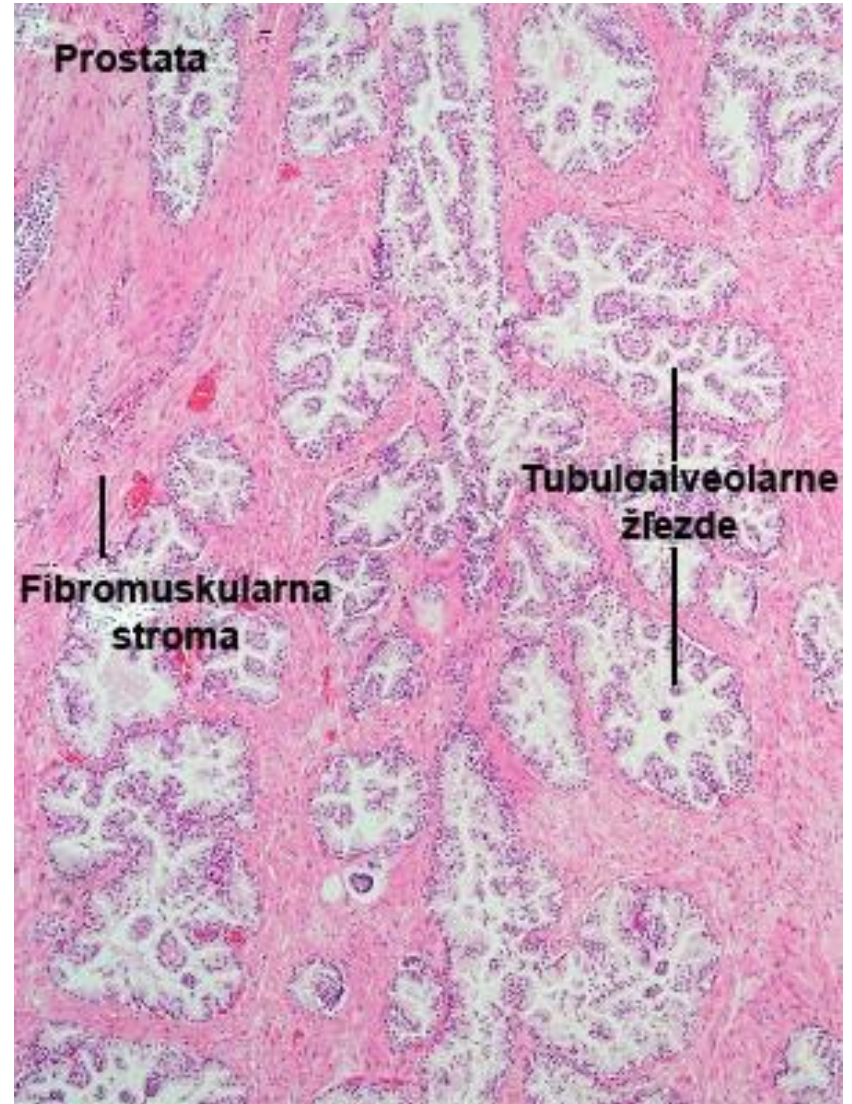
Prostate

- The parenchyma is composed of a large number of tubuloalveolar glands of different sizes, which are arranged radially in three concentric layers around the urethra.
- The smallest glands are closest to the urethra, they look like intussusceptions of its mucosa, so they are called mucous glands.



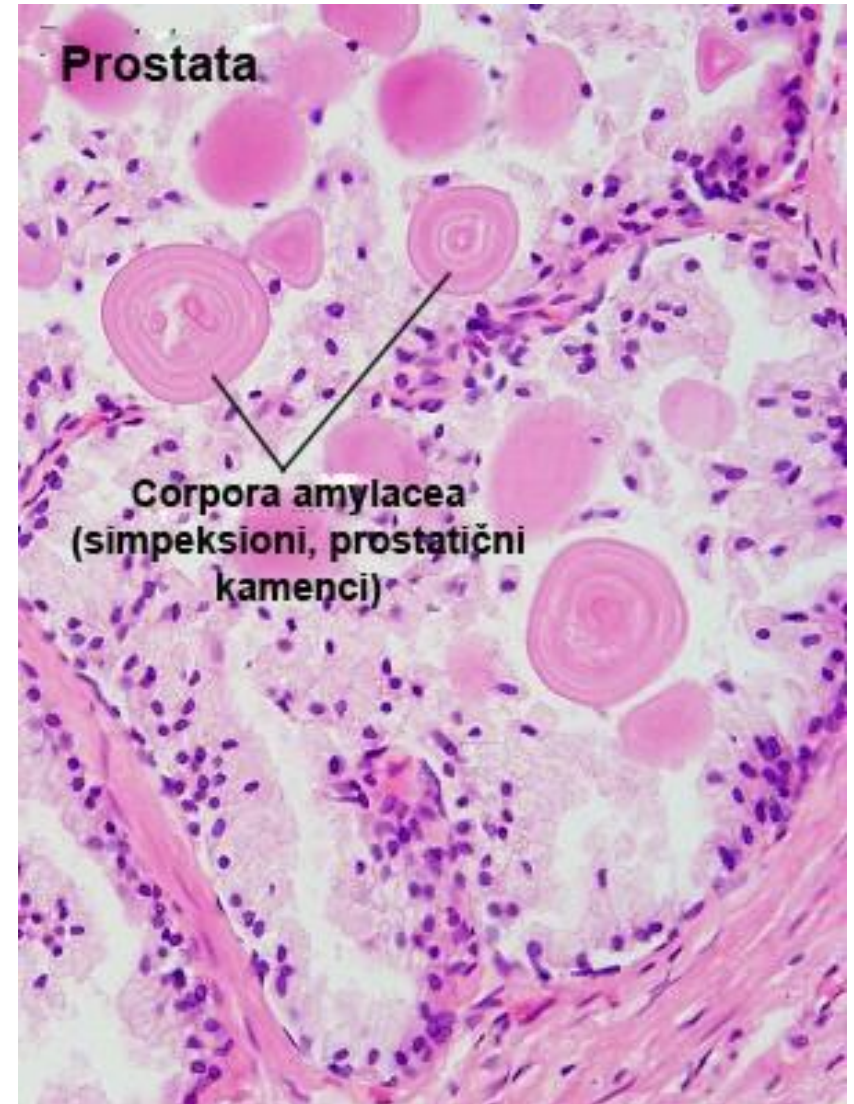
Prostate

- The second layer consists of somewhat larger submucosal glands, which also flow into the urethra through their excretory channels.
- In the third, peripherally distributed layer, there are the largest and most branched so-called true prostate gland.



Prostate

- Lumens of tubuloalveolar glands are often filled with circular or oval prostatic stones (corpora amylacea).
- Prostatic stones consist of calcified glycoproteins.
- Their number increases with age.

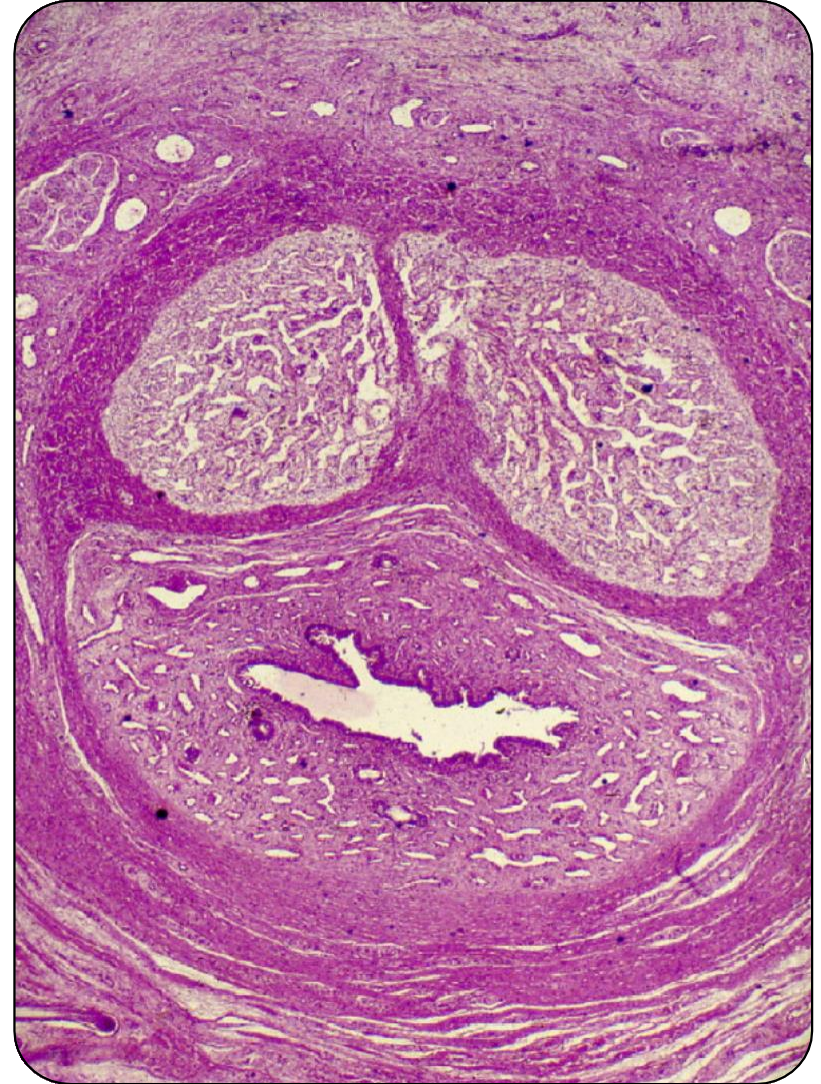

Bulbourethral glands (gll. bulbourethrales)

- Bulbourethral glands are small, paired, round, tubuloalveolar glands that synthesize mucoid secretion during copulation.
- Located on both sides of the urethra, they pour secretions into it through the excretory canal.
- The secretory epithelium of these glands is single-rowed, and the shape varies depending on the filling, from tall cylindrical, through cuboidal to plate-like.

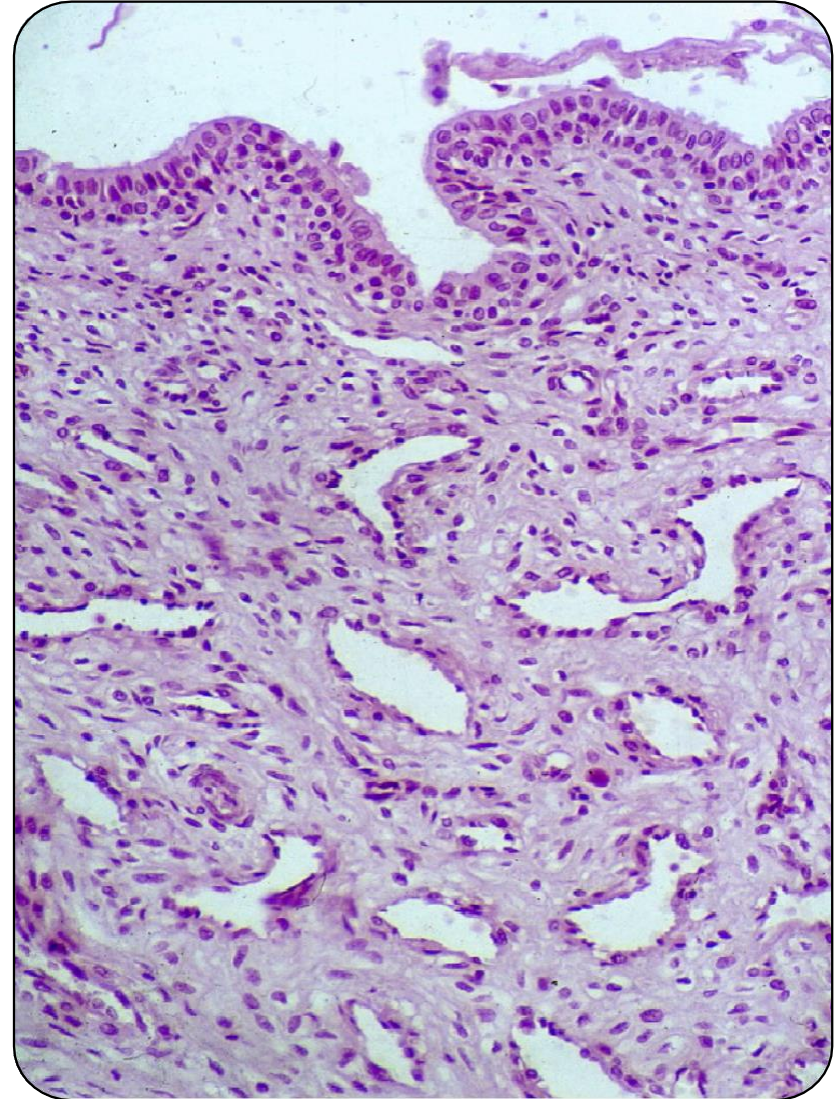
Penis

- The penis is the final organ of the male genital and urinary tract.
- It consists of three erectile bodies: two corpora cavernosa, located on the dorsal side and corpus spongiosum located on the ventral side.
- Through the corpus spongiosum
- passes through the pars spongiosa of the urethra.



Penis

- At its anterior end, the corpus spongiosum expands into the glans penis.
- Each erectile body is surrounded by a tunica albuginea, from which trabeculae enter the interior of the erectile bodies.
- Between the trabeculae in the cavernous bodies there are sinuses or caverns, and in the spongy body there are venous anastomoses.
- During an erection, these cavities are filled with blood.



Penis

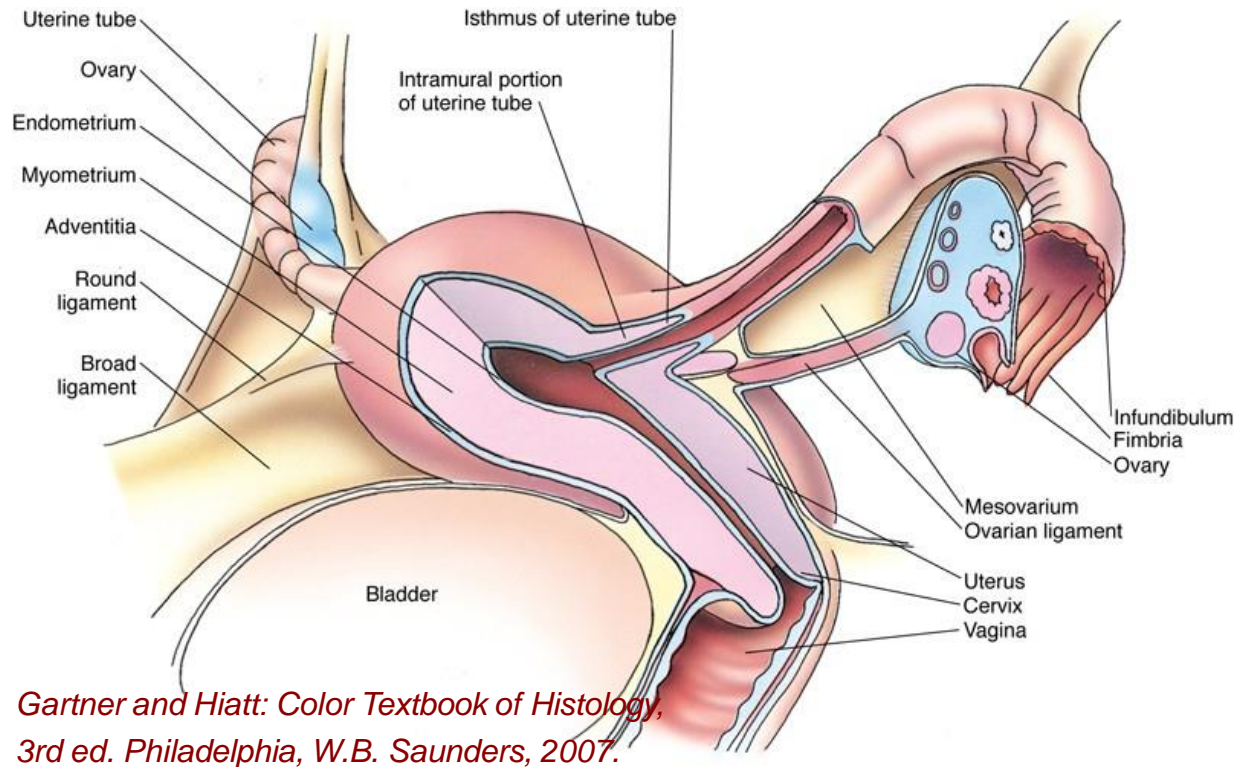
- The erectile bodies are vascularized by the deep and dorsal arteries of the penis.
- Deep arteries pass through the corpora cavernosa and give three types of branches:
- arteriovenous anastomoses - connect the dorsal arteries with the draining veins on the surface of the cavernous bodies;
- Helicine arteries - they empty into the sinuses of the cavernous body, so they are also designated as functional branches;
- small branches or metarterioles – nutritional branches, feed the trabeculae and drain into the caverns.
- Dorsal arteries are located between the capsule of the erectile bodies and the fascia of the penis, they feed the tunica albuginea and larger trabeculae, and a small part of the blood from them flows into the sinuses of the erectile bodies.

Penis

- The skin of the penis is thin, pigmented and mobile.
- It contains a lot of elastic fibers and modified sebaceous glands
- (Tyson's glands).
- On the glans, it passes into squamous epithelium without armature, and then into the epithelium of the urethra.
- It contains free nerve endings and Meissner's corpuscles, and numerous genital corpuscles in the skin of the glans.

Female reproductive
the system

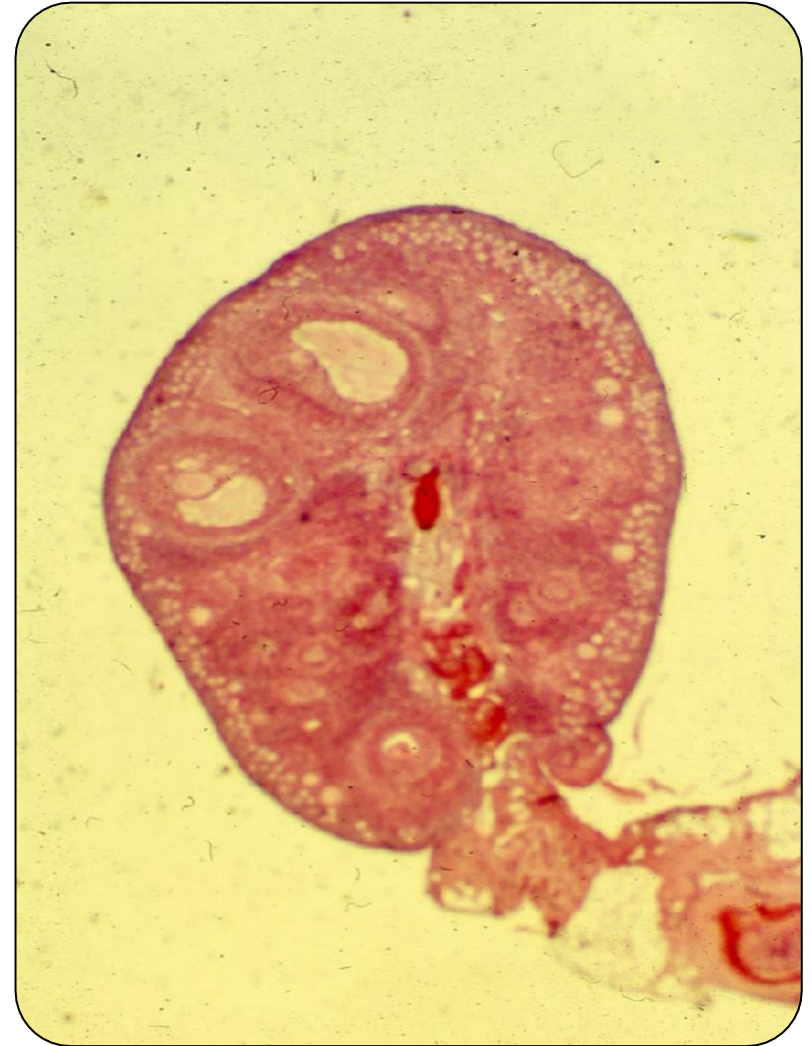Female reproductive system



- The female reproductive system consists of:
- internal reproductive organs: paired ovaries, uterus and vagina
- external genitalia

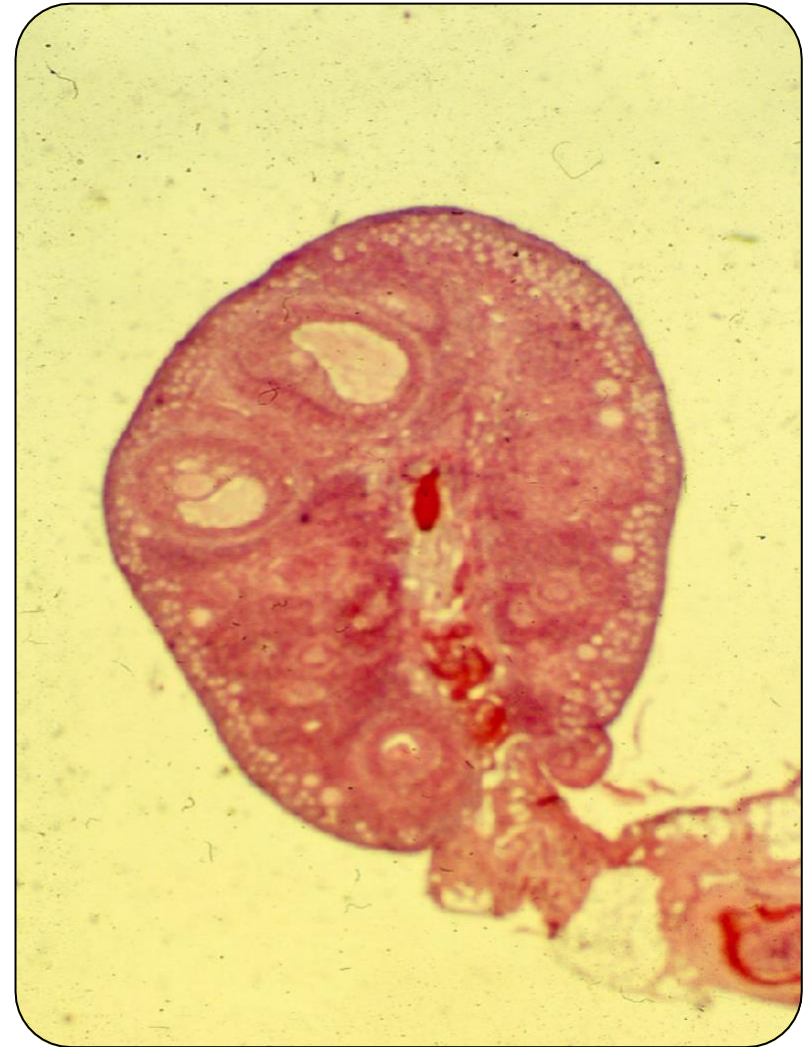Ovary

- The ovary is covered with single-row cuboidal epithelium - germinal epithelium - modified peritoneum.
- Beneath this epithelium is the tunica albuginea, a connective tissue capsule whose collagen fibers are oriented parallel to the surface of the ovary.



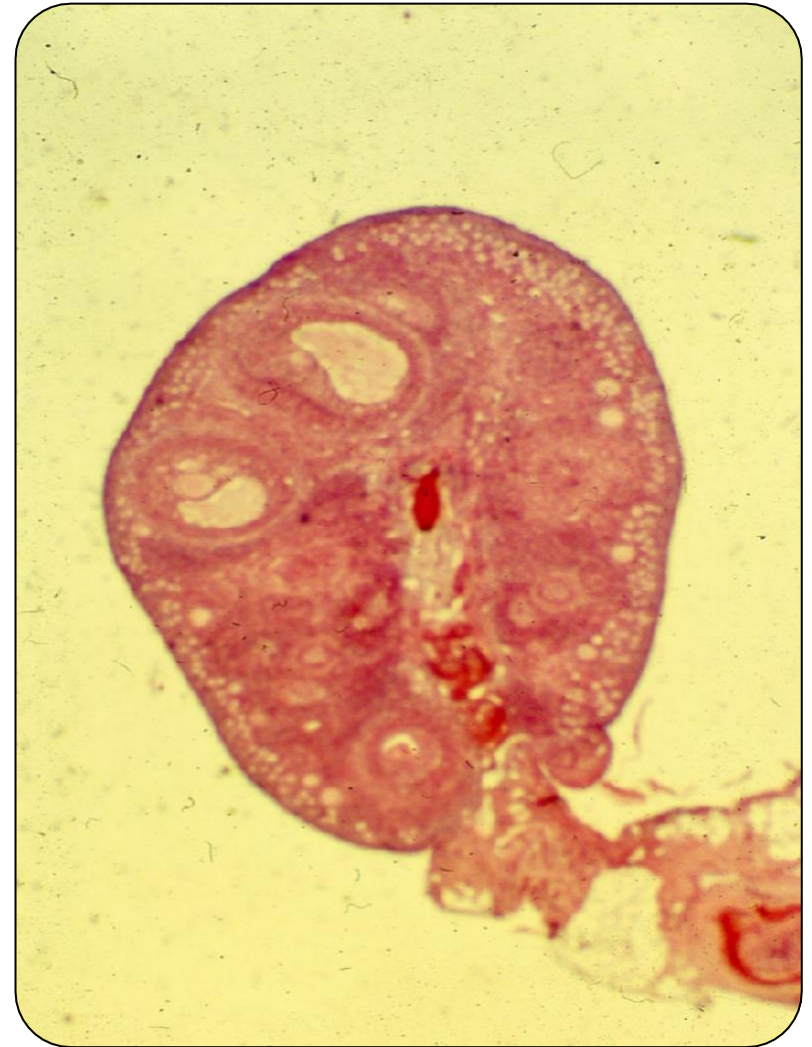Ovary

- The ovary consists of two basic parts:
- Cortex, which is distinctly cellular (cortex ovarii)
- Medulla (medulla ovarii)



Ovary

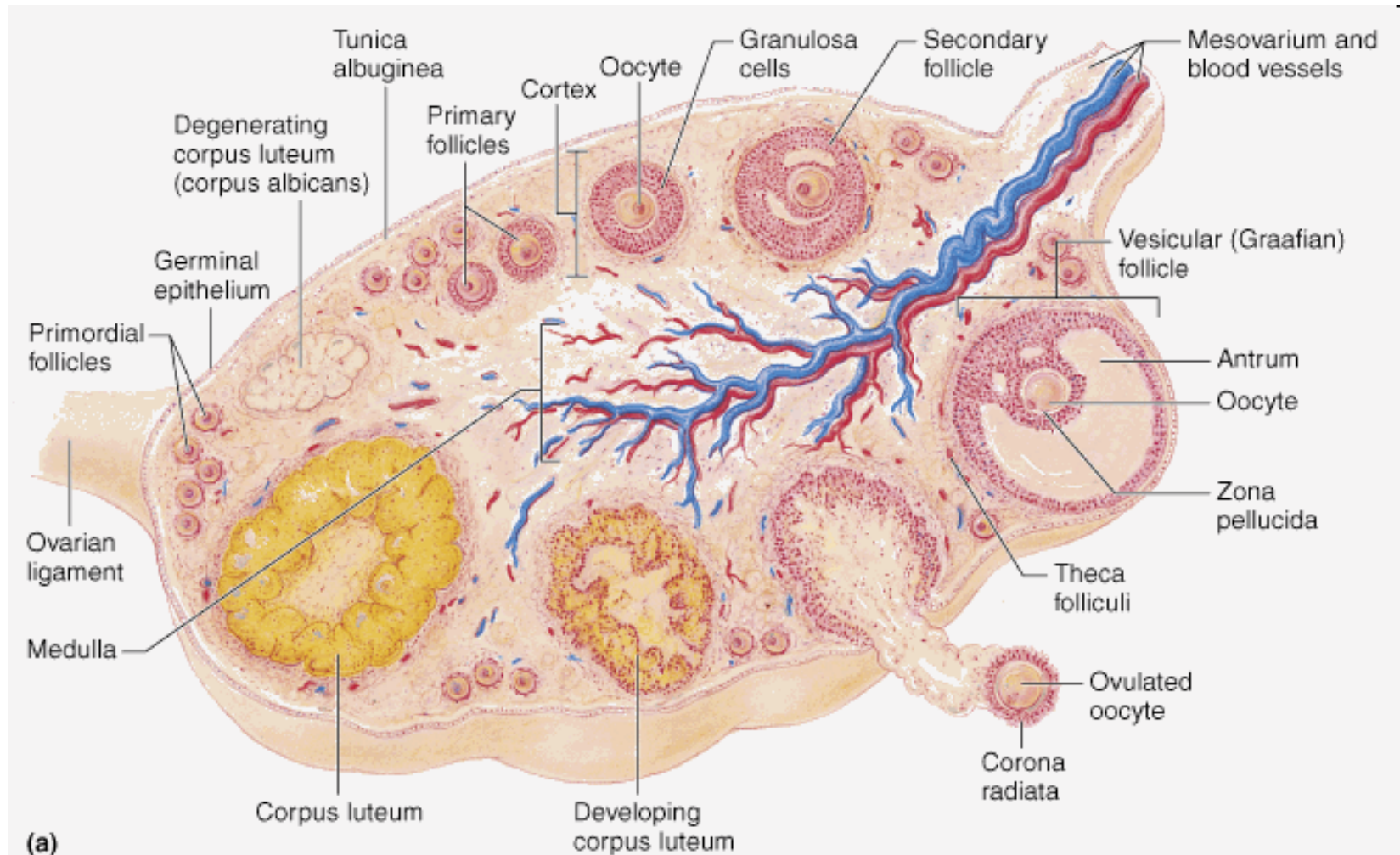
- The cortex of the ovary is made up of:
- Stroma consisting of connective tissue fibers and fibroblast-like stromal cells;
- Parenchyma containing egg follicles in various stages of development.
- The medulla contains large blood vessels, lymphatic vessels and nerve fibers immersed in the connective tissue stroma, as well as the remnants of the Wolffian duct - rete ovarii.



Ovarian follicles

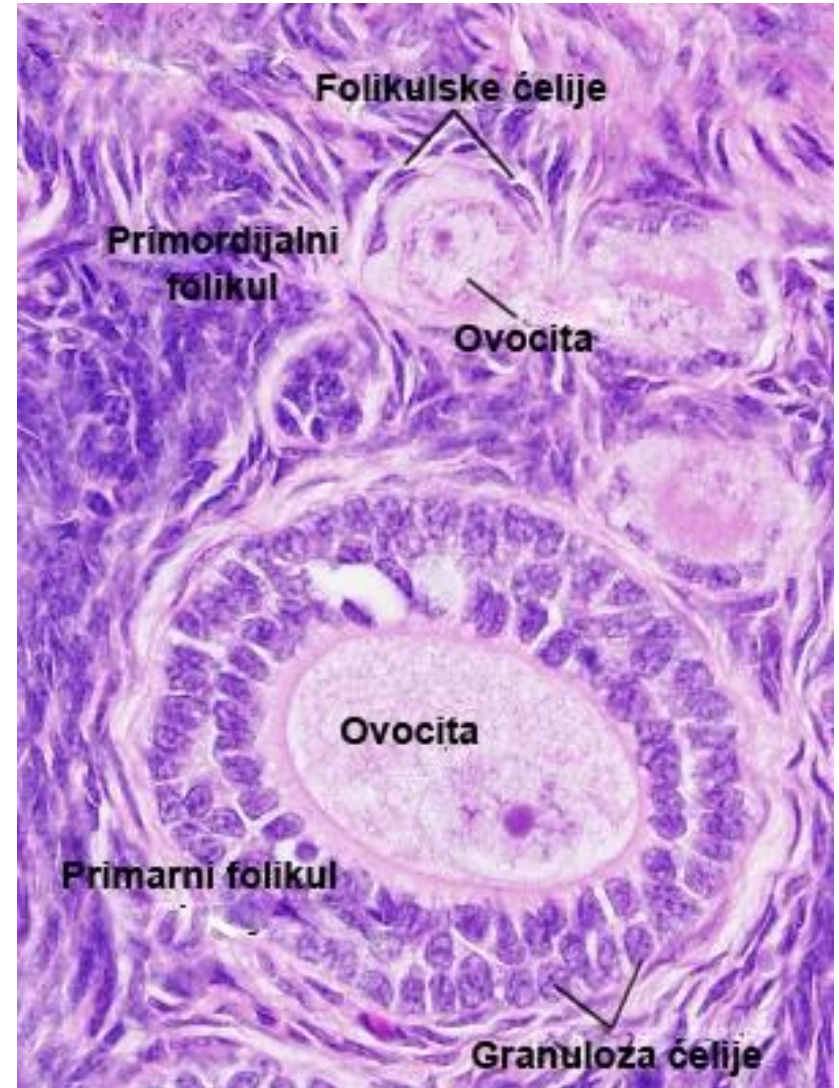
- Ovarian follicles contain an egg cell with one or more layers
- follicular (granulosa) cells that form an envelope around it.
- They are located in the cortex of the ovary and there are as many of them as there are egg cells.
- The appearance and size of egg follicles depend on the stage of development.
- The vast majority of follicles are dormant (dormant follicles) and never develop.
- A smaller number grow and mature each month (maturing follicles).
- Usually only one of them reaches full maturity during the month (mature or preovulatory follicle).
- Maturation of follicles is called folliculogenesis.
- During folliculogenesis, follicles pass through several stages: primordial, primary unilamellar, primary multilamellar (the gonadotropin-independent phase lasts until this stage), and then the secondary and tertiary follicle (gonadotropin-dependent phase of folliculogenesis).

Ovarian follicles



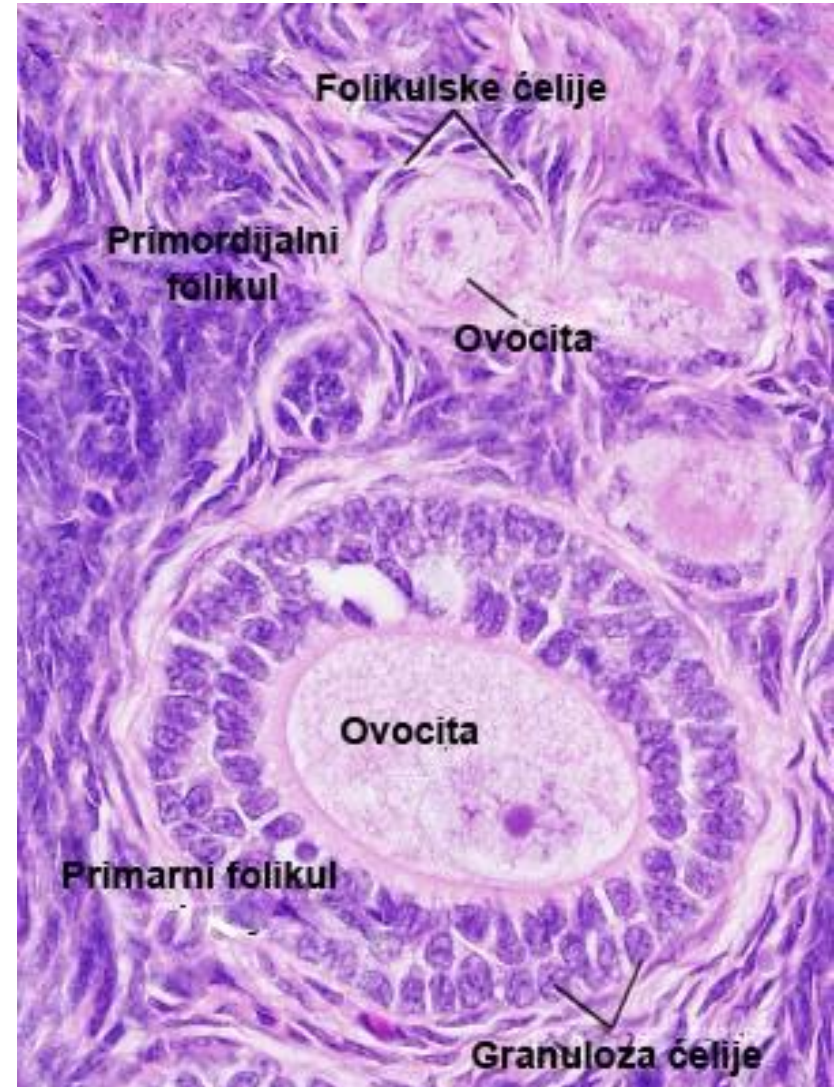
Primordial follicle

- Primordial follicles - located directly under the tunica albuginea.
- The smallest and most numerous follicles.
- Each primordial follicle consists of a round primary oocyte (in the prophase of the first meiosis; less pronounced organelles) surrounded by several flattened follicular cells (flattened nucleus, scarce organelles).
- Follicular cells are connected by desmosomes and surrounded by a thick basement membrane (the follicle is isolated from the surrounding stroma).



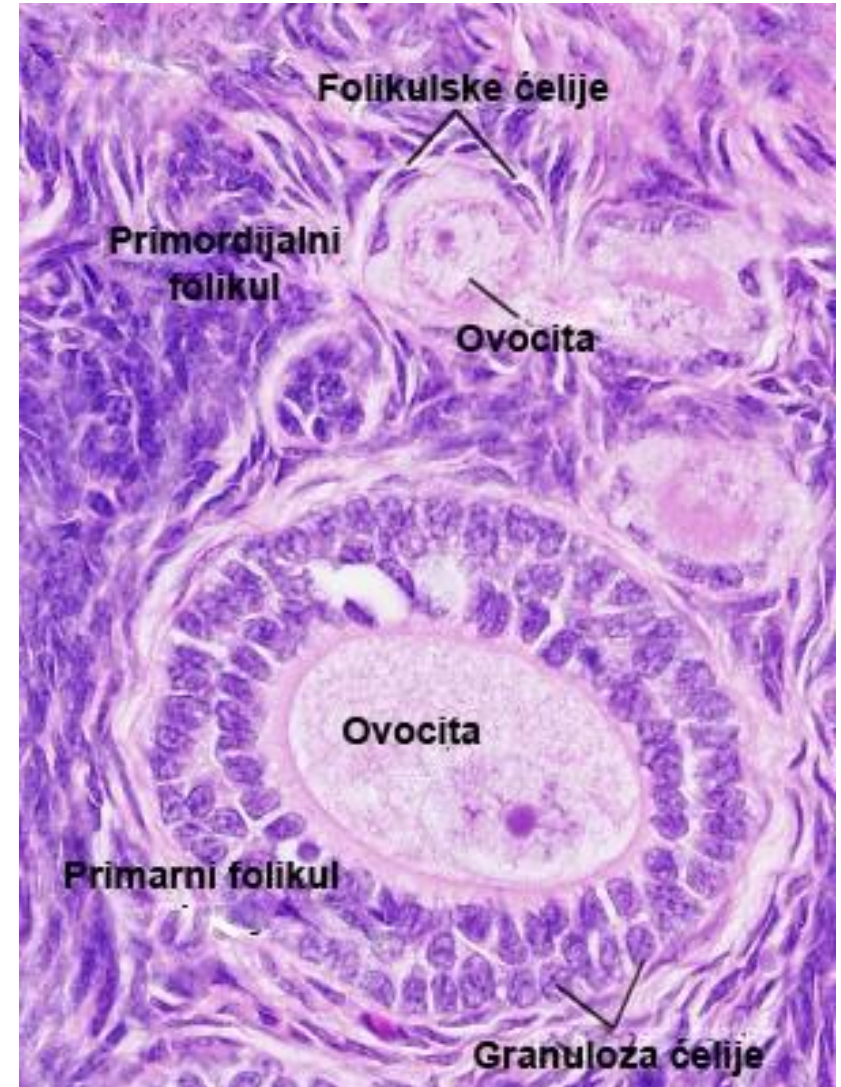
Primary follicle

- The primary follicle is the first stage of growth and maturation of the oocyte, follicle cells and stromal cells around the follicle.
- The oocyte grows and the organelles of the synthetic pathway develop.
- It begins to synthesize glycoproteins that spill over its surface - the zona pellucida.
- Follicular cells become cuboidal and surround the oocyte in a single layer.
- A primary unilamellar follicle is formed.



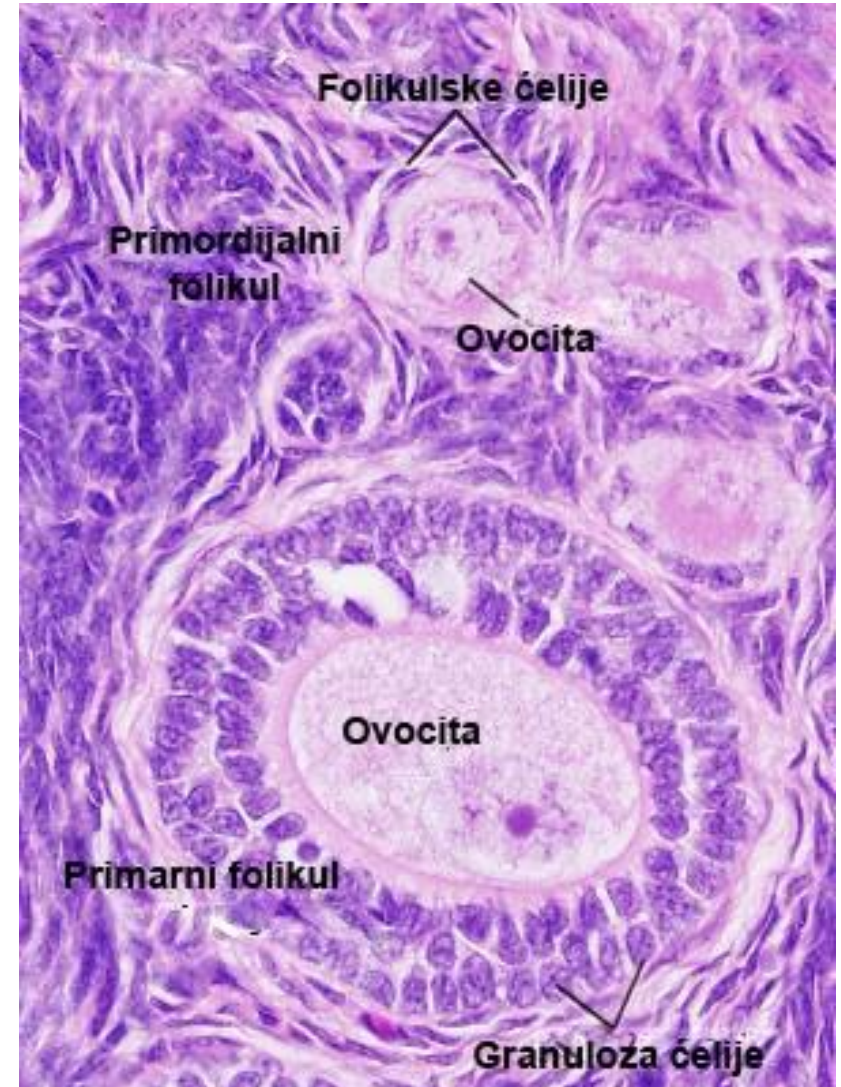
Primary multilamellar follicle

- The oocyte continues to grow and synthesize more and more glycoproteins - the zona pellucida becomes thicker.
- Intensive proliferation of follicular cells creates a multilayered covering similar to the epithelium (up to 12 layers of cells), so the follicle at this stage is called a primary multilamellar follicle.
- Follicular cells become small compared to the grown oocyte and are called granulosa cells.



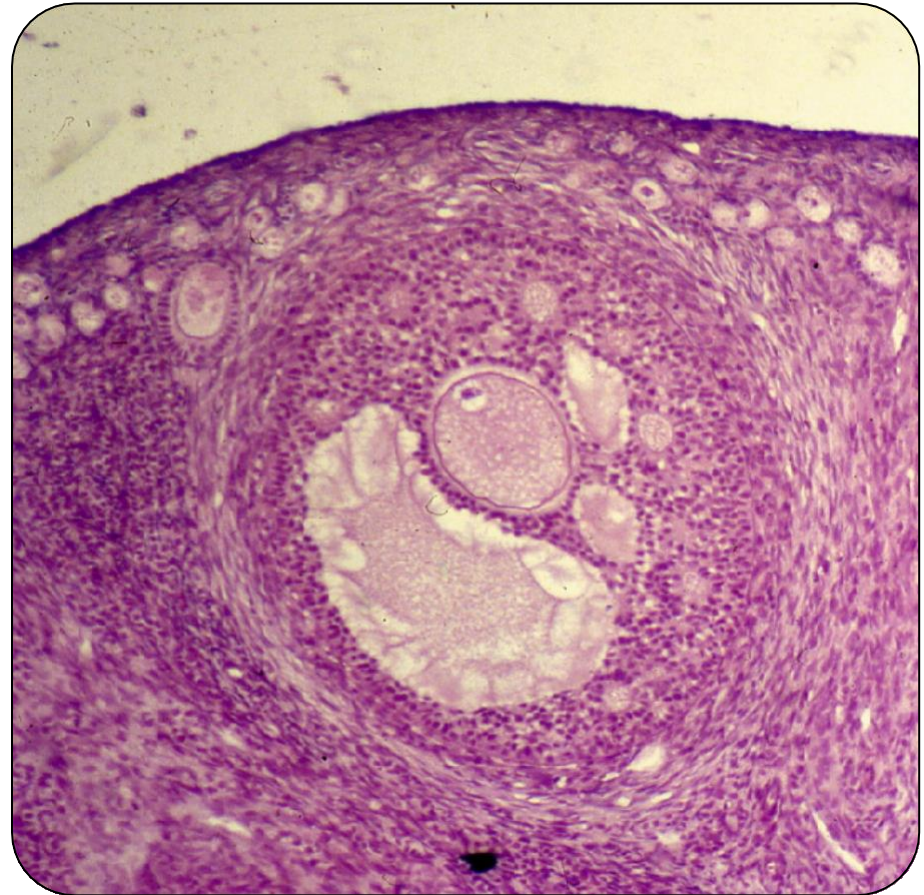
Primary multilamellar follicle

- With the development of the primary multilamellar follicle, the connective tissue of the stroma thickens, creating a two-layer envelope - theca follicles.
- About 10 menstrual cycles (about 290 days) are required for the complete development of the primary multilamellar follicle from the primordial follicle.
- They develop without hormonal stimulation (they also exist in children before puberty).
- For the further development of the follicles, FSH is necessary under the influence of which several primary multilamellar follicles continue to grow in each ovarian cycle.



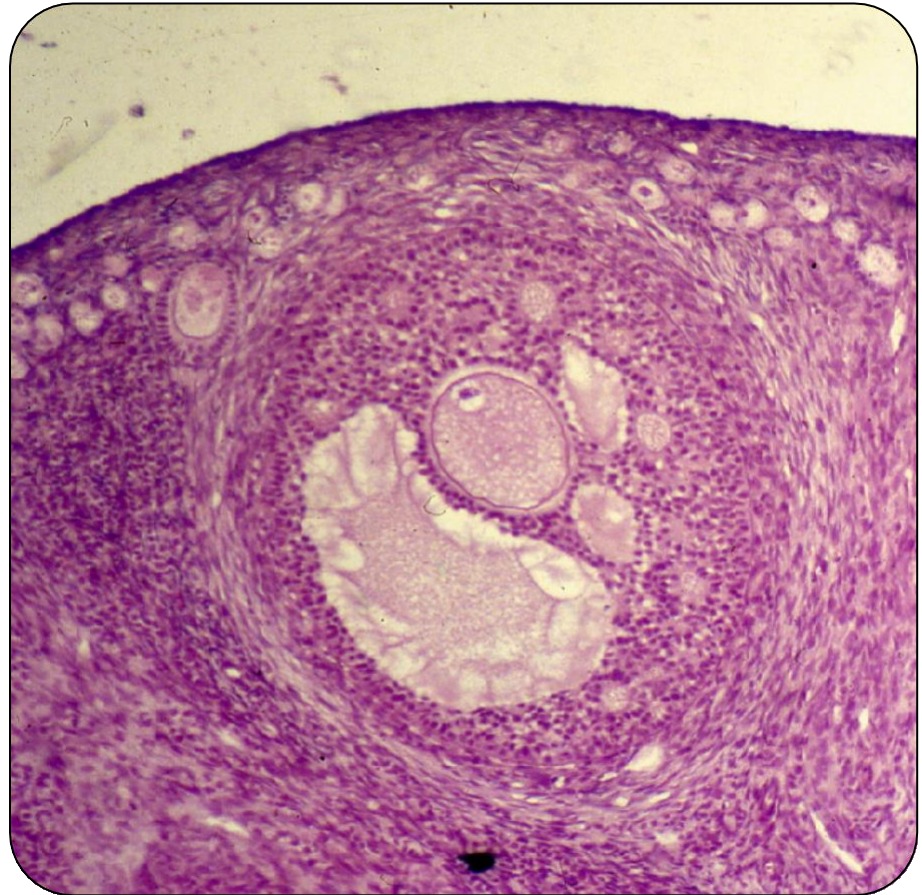
Secondary follicle

- Secondary ovarian follicles arise from primary multilamellar follicles.
- Due to the intensive proliferative and secretory activity of granulosa cells, the multilamellar follicle increases.
- In the intercellular spaces of the granulosa coat, small cavities filled with a clear liquid can be observed, which converge into antrum follicles.
- The process of forming the antrum is called cavitation, and the follicle with the formed antrum is called a secondary or antral egg follicle.



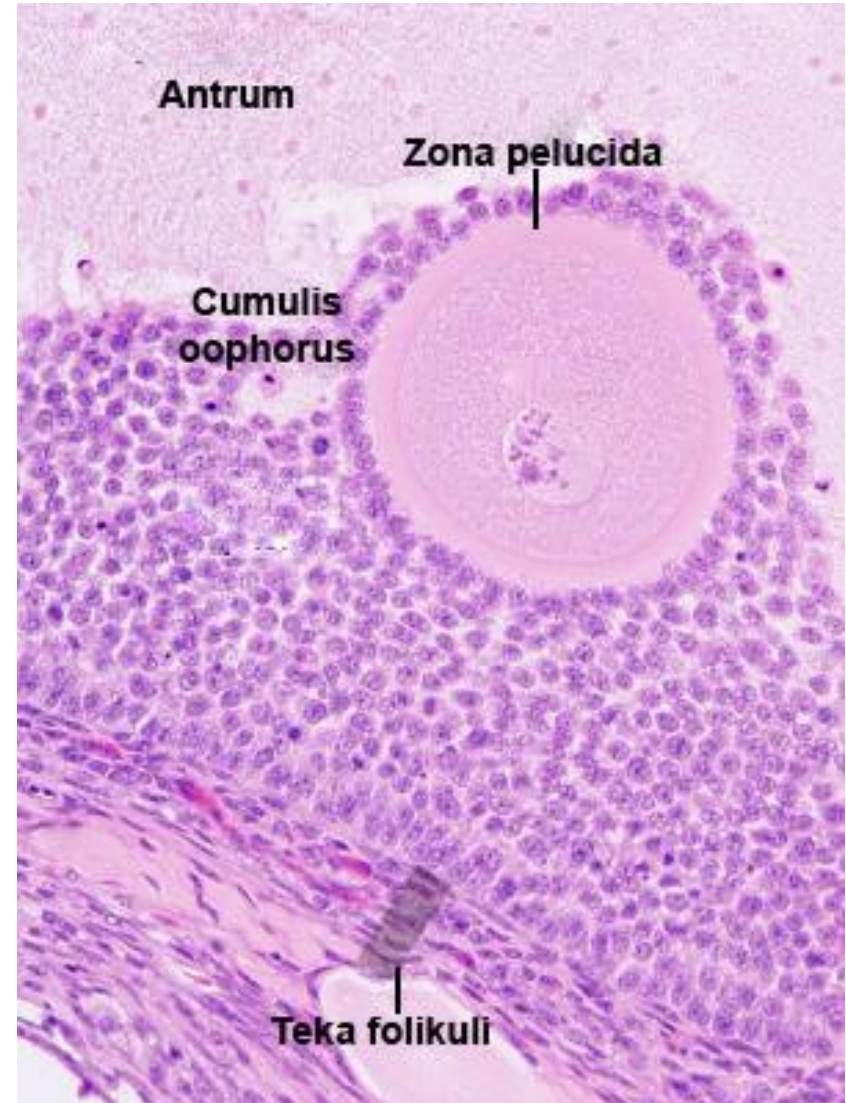
Secondary follicle

- The antrum is filled with a liquid called follicular fluid or liquor folliculi.
- CSF is a transudate of blood plasma.
- It contains steroid-binding proteins that bind estrogen, progesterone and androgens, so the concentration of these hormones in the cerebrospinal fluid is high.
- The cerebrospinal fluid also contains the oocyte maturation inhibitor OMI (prevents the completion of the initiated division) and regulatory hormones - inhibins, activins and follistatins that regulate the secretion of FSH (secreted by granulosa cells).



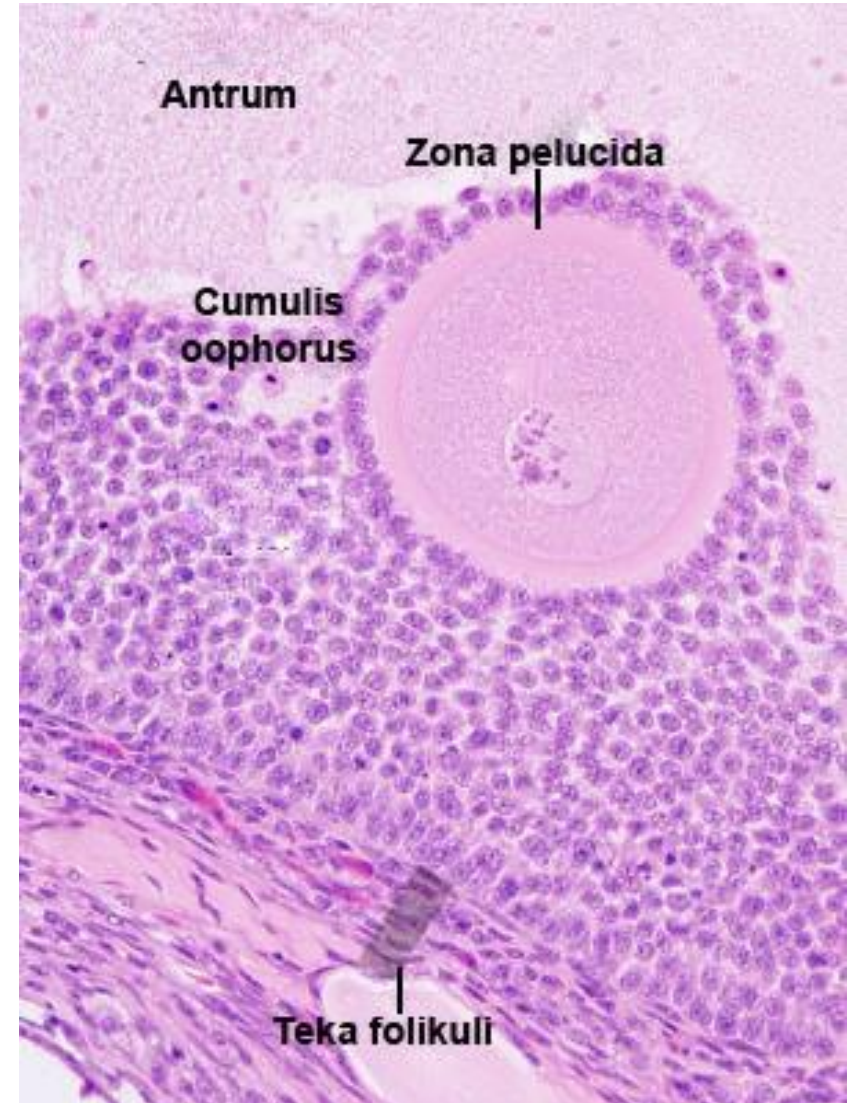
Secondary follicle

- With the appearance of the antrum, the granulosa cells are separated into a multi-layered envelope - the stratum granulosum (between the basal membrane of the follicle and the antrum) and the envelope around the ovum.
- The layer of cubic granulosa cells that immediately surrounds the egg cell is called the corona radiata.
- The antrum pushes the ovum eccentrically, so it protrudes with its envelope of granulosa cells into the lumen of the antrum, forming a hill - cumulus oophorus.



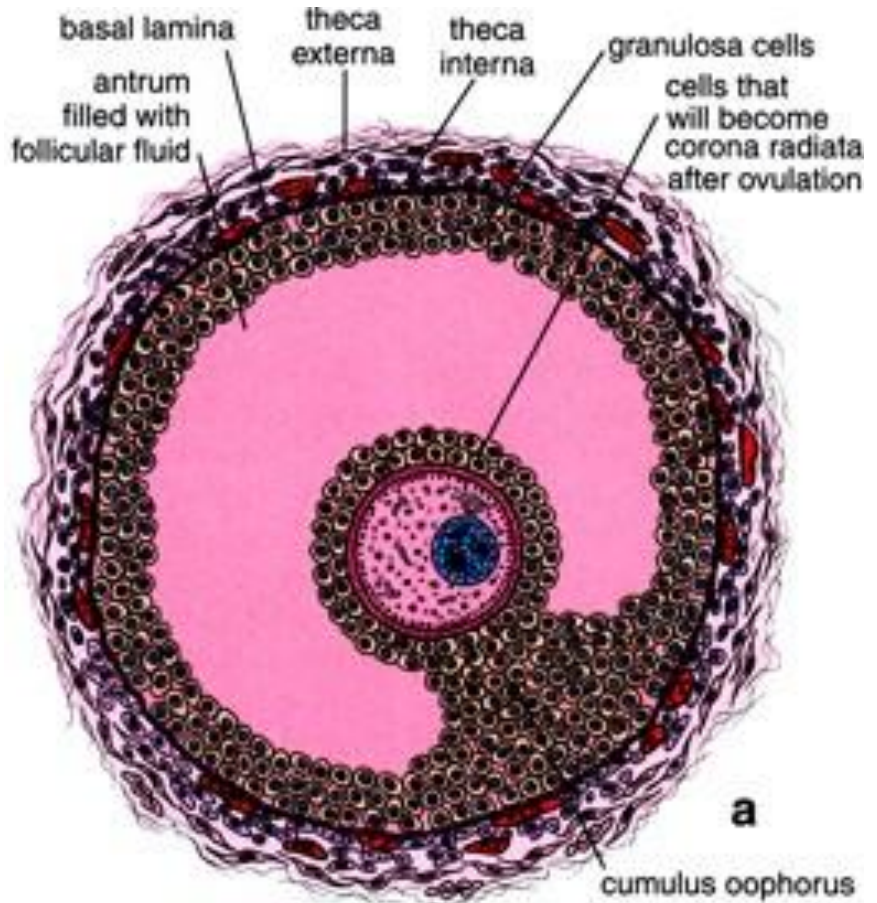
Secondary follicle

- The secondary follicle is surrounded by a theca follicle which has two layers.
- The theca interna is located just below the basement membrane of the follicle.
- It contains a rich network of blood vessels (they nourish the follicle by diffusion) and cells that under the influence of LH synthesize androstenedione, which diffuses to the cells of the stratum granulosum and is converted into estradiol (the aromatase enzyme of the granulosa cells).
- Theca externa is the outer layer composed of fibrous connective tissue and rare smooth muscle cells.



Tertiary De Graaff follicle

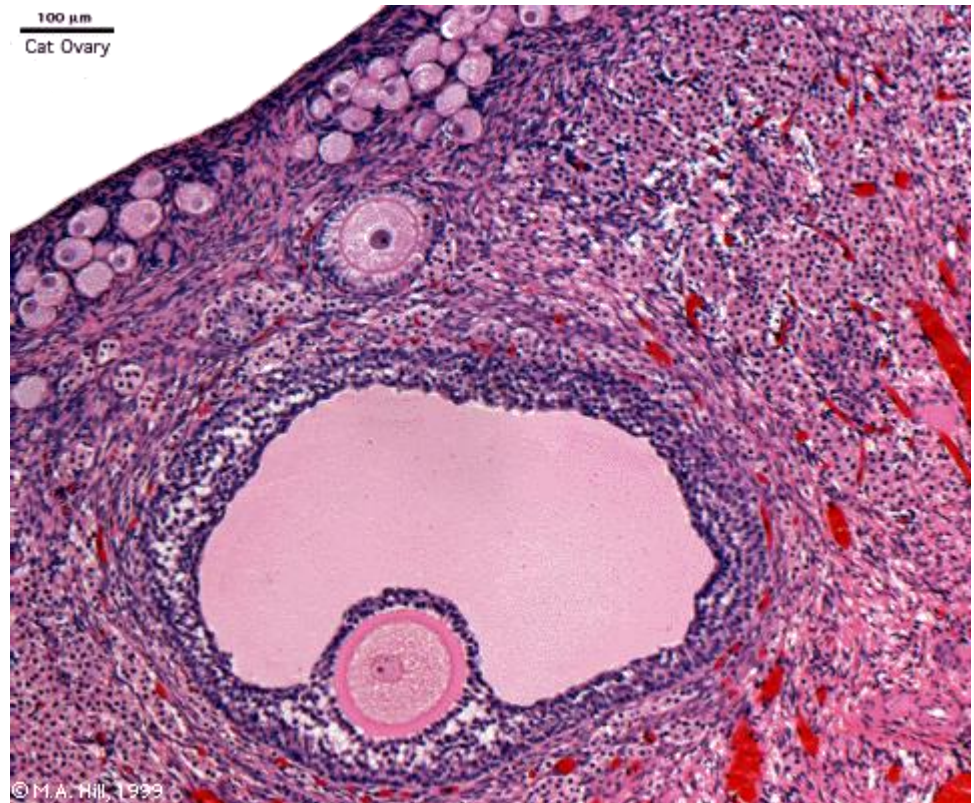
- The growth of the secondary follicle (expansion of the antrum) gives rise to the tertiary De Graff follicle.
- Due to the large amount of cerebrospinal fluid, the granular layer is thinned - the cystic form.
- Before ovulation, the ovum (with corona radiata) breaks away from the follicle wall and floats freely in the follicular fluid.
- Around the follicle is a thick layer of theca.
- From the beginning of cavitation to the formation of the preovulatory follicle, 60 days pass.



MATURE GRAAFIAN FOLLICLE

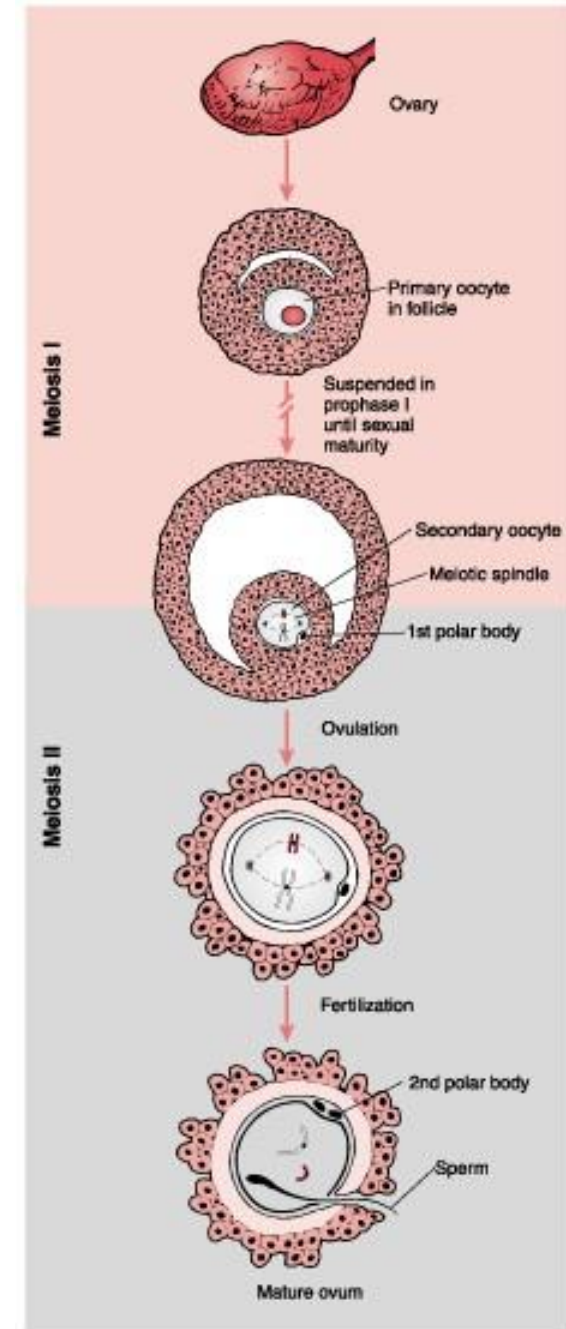
Tertiary De Graaff follicle

- The entire process of folliculogenesis from the moment of activation of the primordial follicle to the emergence of a mature follicle takes almost a year.
- Before ovulation, there is a sudden surge of LH hormone from the adenohypophysis.
- Under the influence of this hormone, the primary oocyte completes the started division.
- Throughout folliculogenesis, she was in the prophase of the first meiosis, which began in the fetal age.



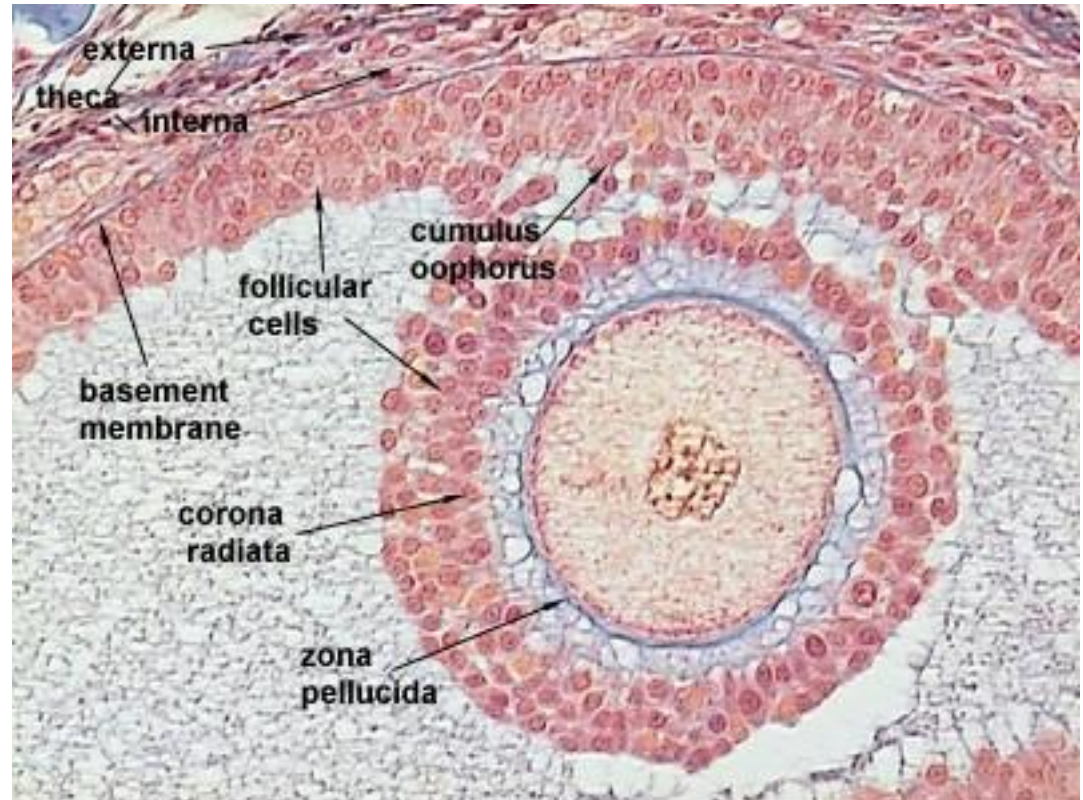
De Graaf's follicle

- The first meiotic division ends in the De Graaf follicle with the division of the primary oocyte and the formation of the secondary oocyte and the first polar body.
- Immediately afterwards, the secondary oocyte enters the second meiotic division, which stops at metaphase (in the De Graaf follicle, before ovulation).
- The secondary oocyte completes the second meiotic division after ovulation, if a sperm enters it.

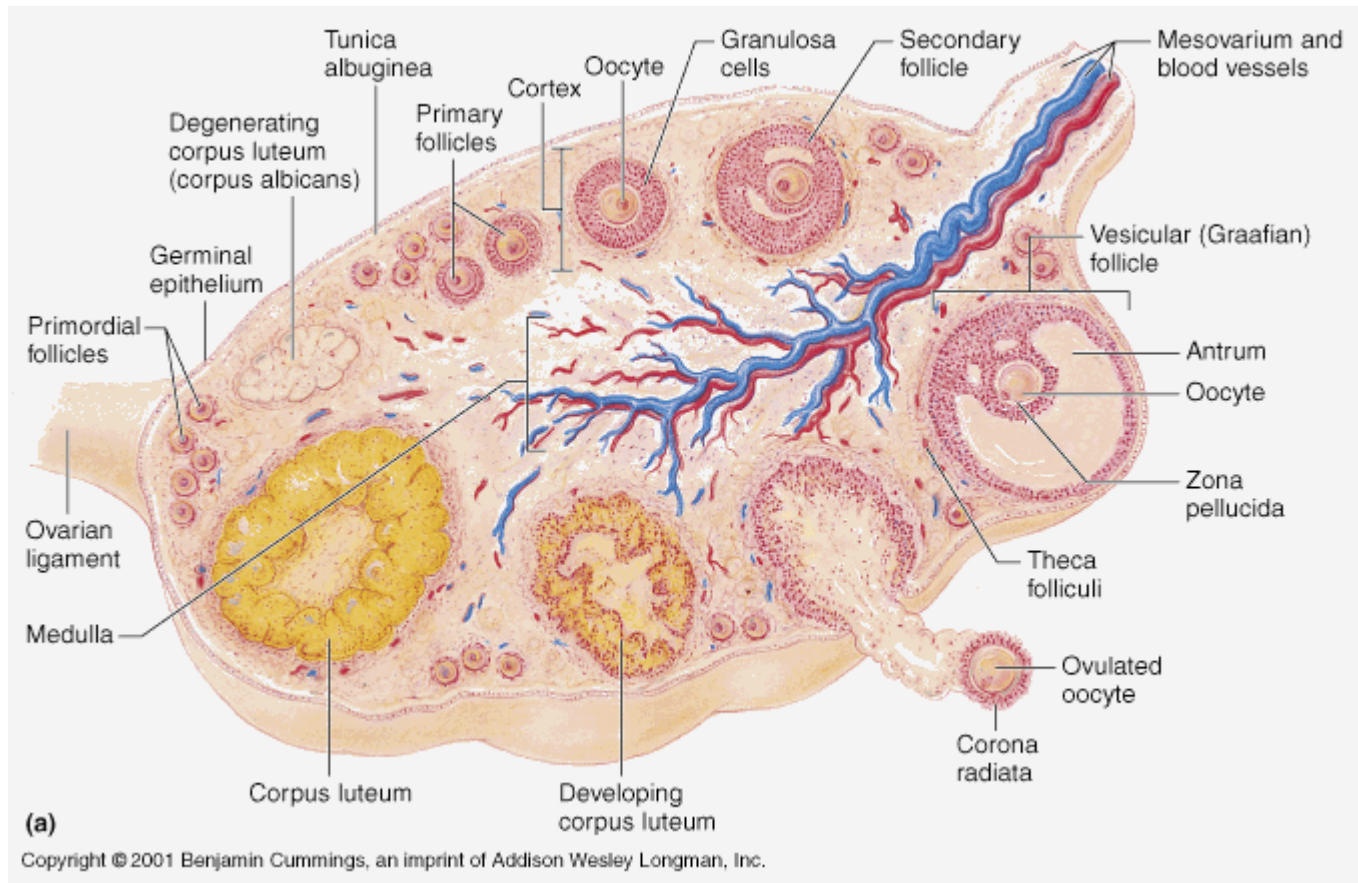


Secondary oocyte

- The secondary ovocyte is a spherical cell (120-150 μm) that has numerous microvilli on its surface.
- It contains a round, eccentrically placed nucleus with fine-grained chromatin and one or (sometimes) more nuclei.
- Near the sail there is a complex of compact organelles
- – Balbian's vitelline body.



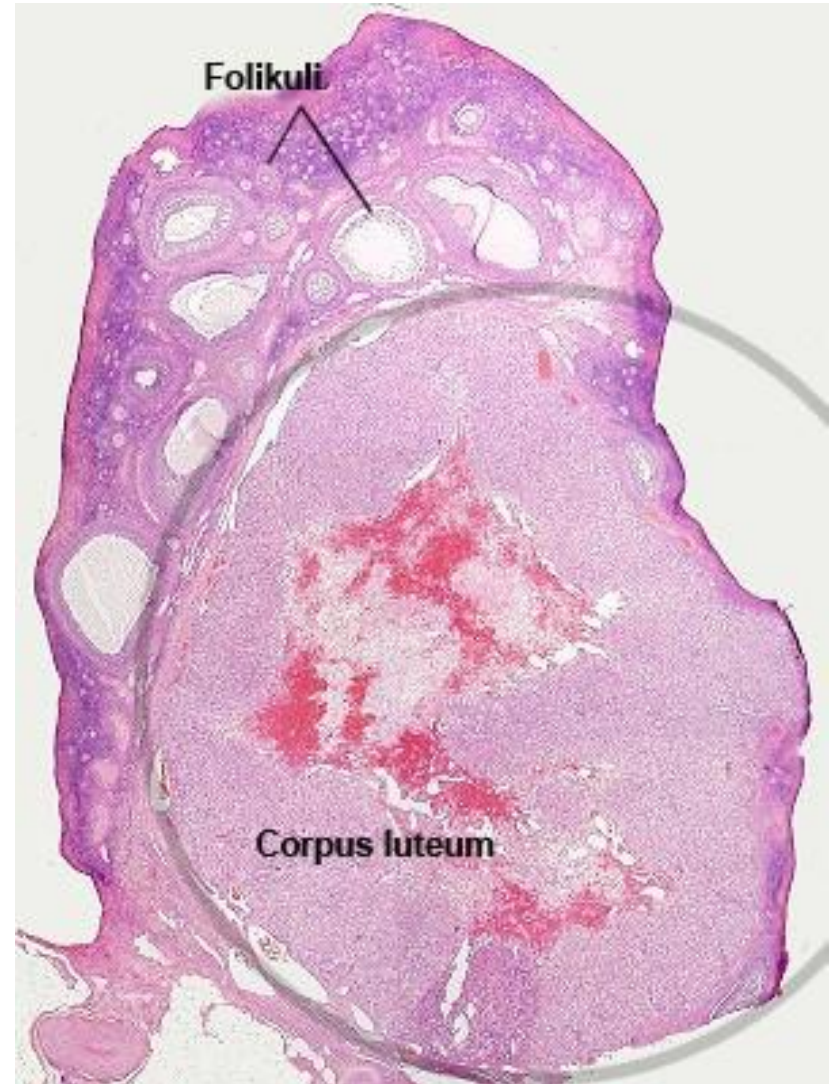
Ovulation



- Ovulation is the physiological process of releasing an oocyte from a mature egg follicle under the influence of LH.
- It is played out by the bursting of the De Graaff follicle, where the egg leaves the ovarian cortex and enters the fallopian tube.

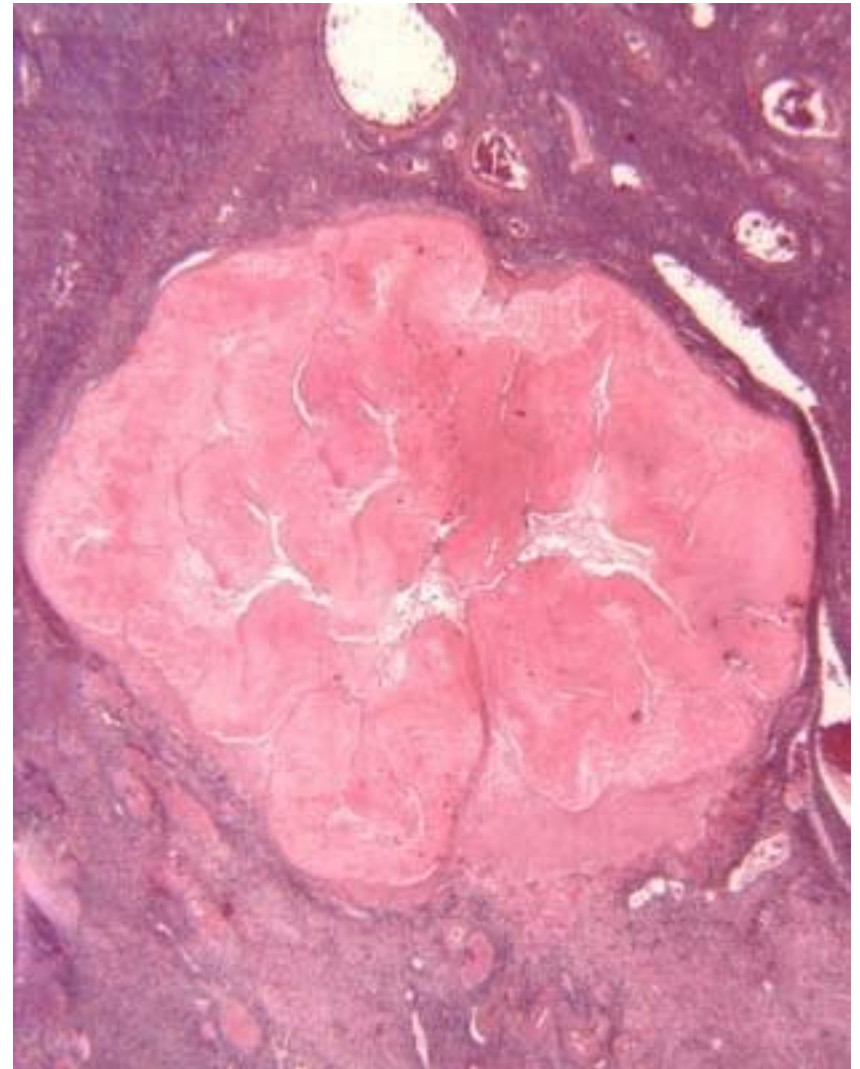
Corpus luteum

- The corpus luteum is a temporary endocrine gland located in the cortex of the ovary.
- It is formed after each ovulation from the remnants of the tertiary follicle.
- The ruptured follicle collapses, its wall becomes wrinkled, and a little blood pours into the antrum, which soon clots - corpus rubrum s. hemorrhagicum.
- Soon, the cavity of the hemorrhagic body penetrates the connective tissue of the ovary, whose macrophages remove the clot.



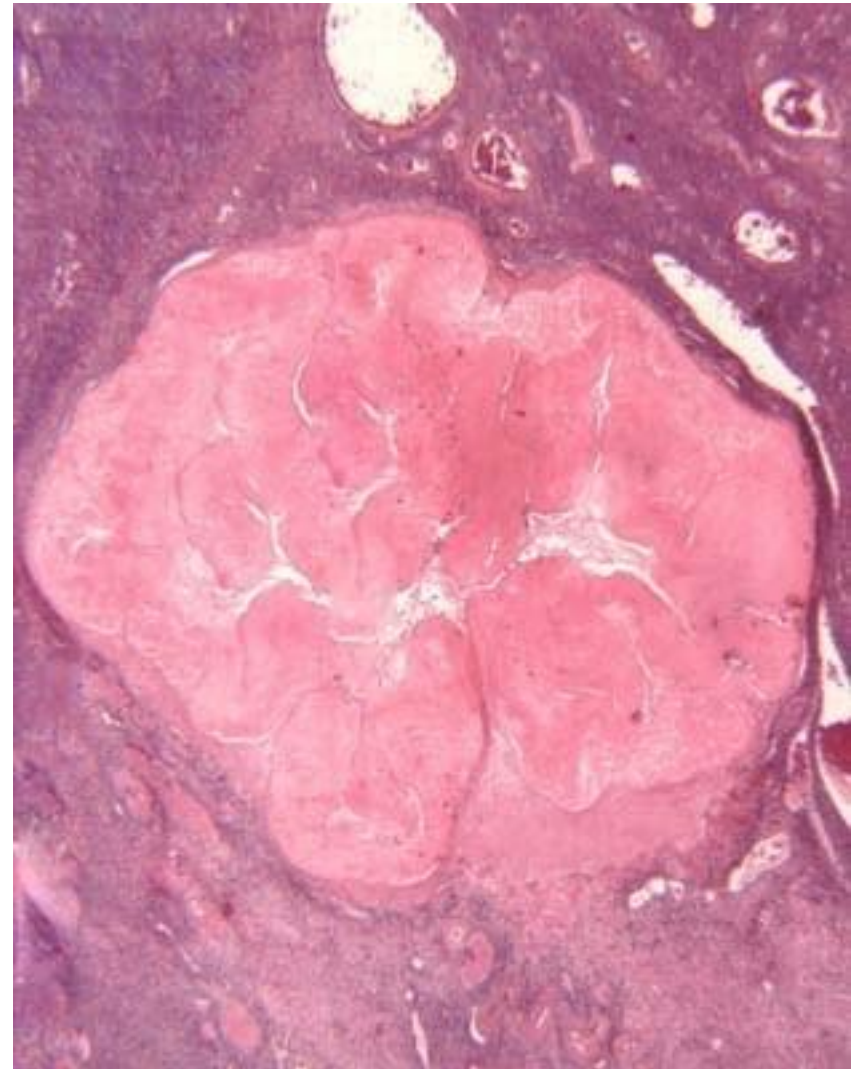
Corpus luteum

- The fate of the corpus luteum depends on the eventual fertilization of the ovum.
- If implantation does not occur, hormonal stimulation by the LH hormone is absent and the corpus luteum experiences regression.
- It is active 10-12 days after ovulation, and the largest amount of hormones is secreted at the end of the first week (after ovulation).
- As the corpus luteum secretes estrogen and progesterone that inhibit the secretion of FSH or LH, with its regression, there is a sudden drop in estrogen and progesterone, which leads to menstruation and the beginning of a new ovarian cycle (under the influence of FSH of the adenohypophysis).



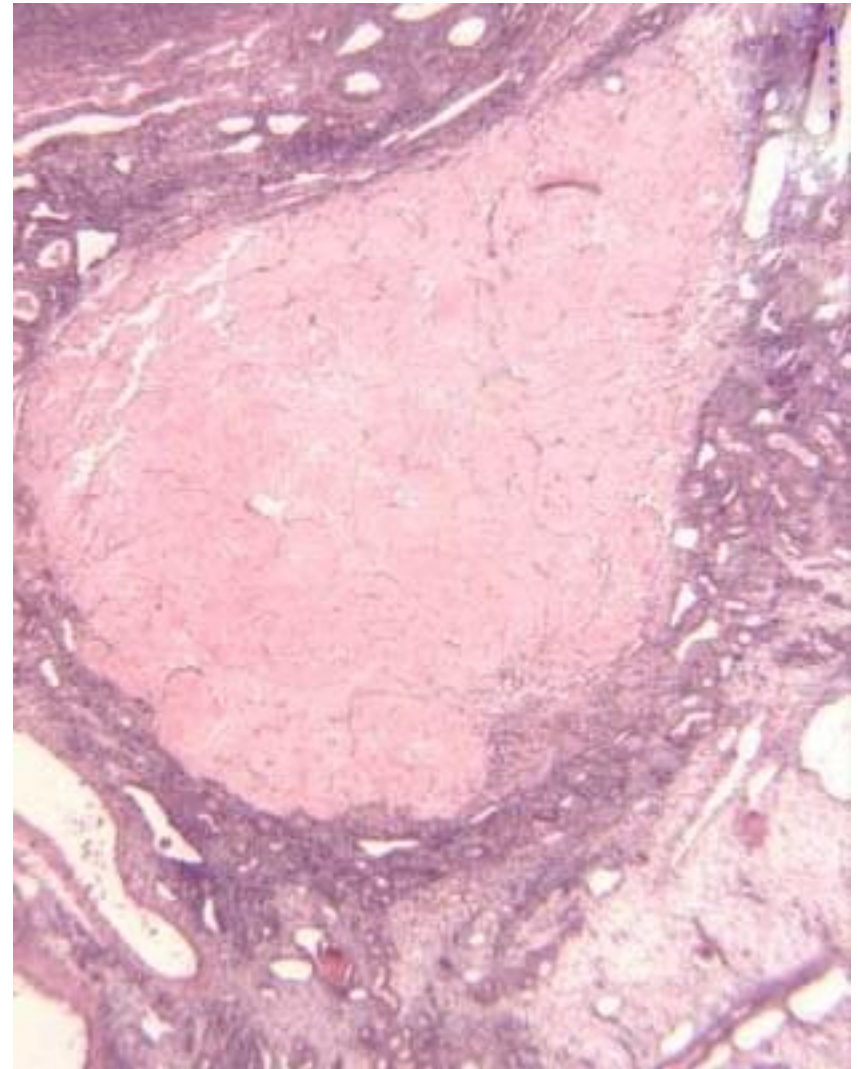
Corpus luteum

- This yellow body that lasts only during one menstrual cycle is called corpus luteum menstruationis.
- Its cells undergo autolysis and are phagocytosed by macrophages.
- At the site of the autolyzed corpus luteum, fibroblasts create white scar tissue - corpus albicans (it sinks into the depth of the cortex, is resorbed for a longer period of time)



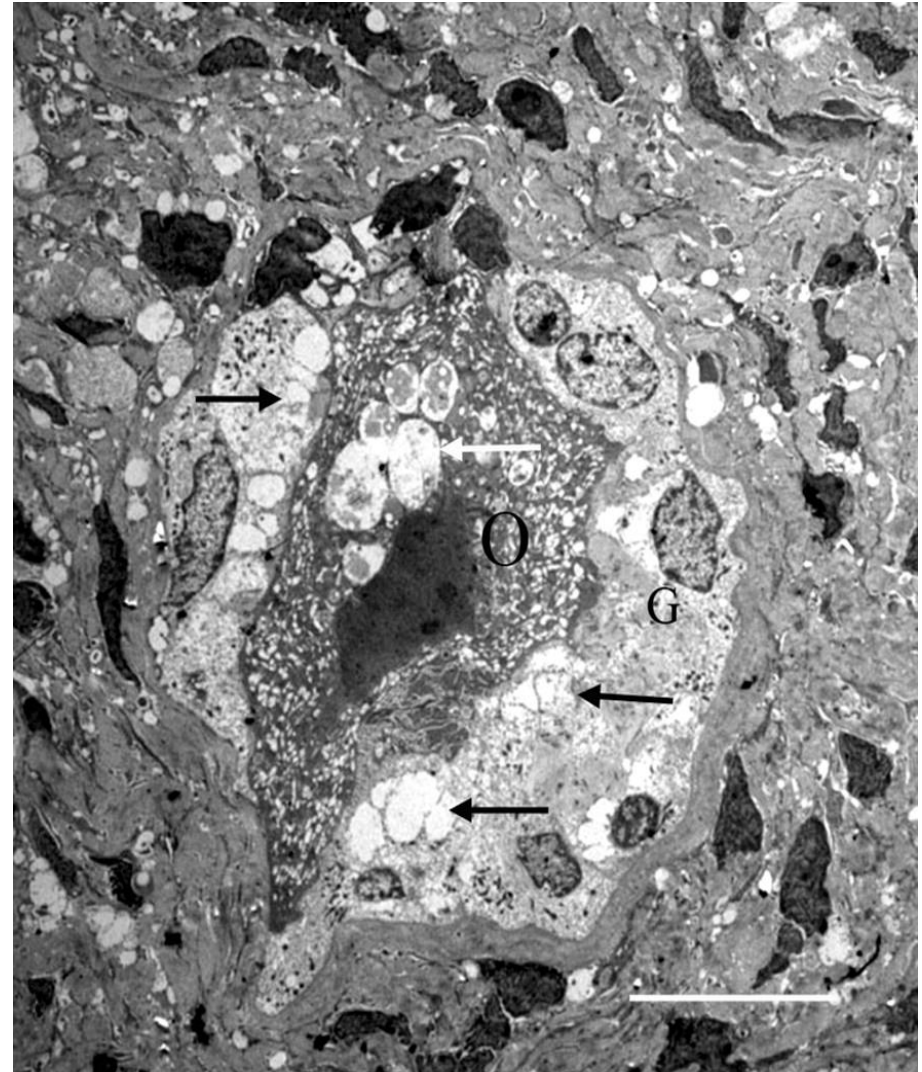
Corpus luteum

- If conception and implantation occur, the created corpus luteum continues to grow under the influence of human chorionic gonadotropin (HCG) synthesized by trophoblast cells of the placenta.
- In the third month of pregnancy, the corpus luteum occupies approximately half of the ovary (about 2.5 cm).
- This form of the corpus luteum that hormonally supports pregnancy is called the gravid corpus luteum or corpus luteum gravidatis.
- From the fourth month of pregnancy, it undergoes involution, and progesterone synthesis is taken over by the syncytiotrophoblast of the placenta.
- The gravid corpus luteum leaves behind a significantly larger corpus albicans.



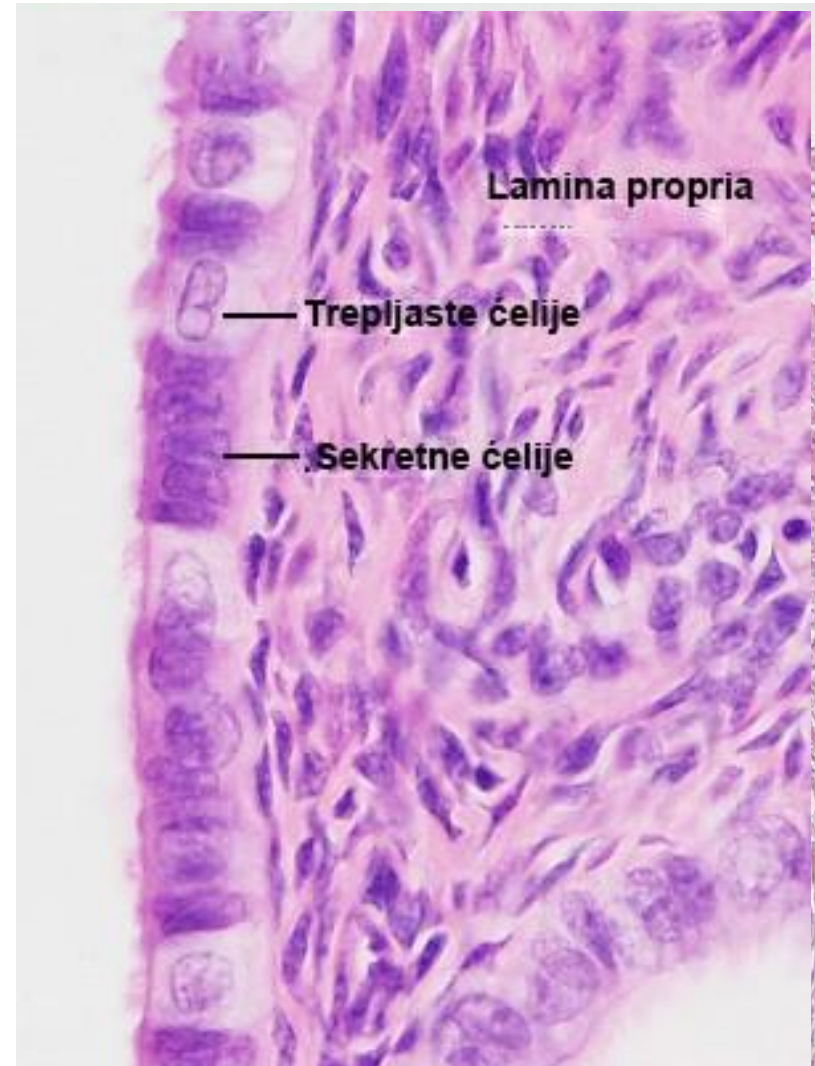
Atresia of egg follicles

- Atresia is a physiological process of deterioration (degeneration) of egg follicles.
- Out of about 5 million egg follicles in the fetal period, only 400-450 mature and burst during ovulation.
- All other follicles are subject to atresia, which affects all developmental stages of follicles from primordial to tertiary.



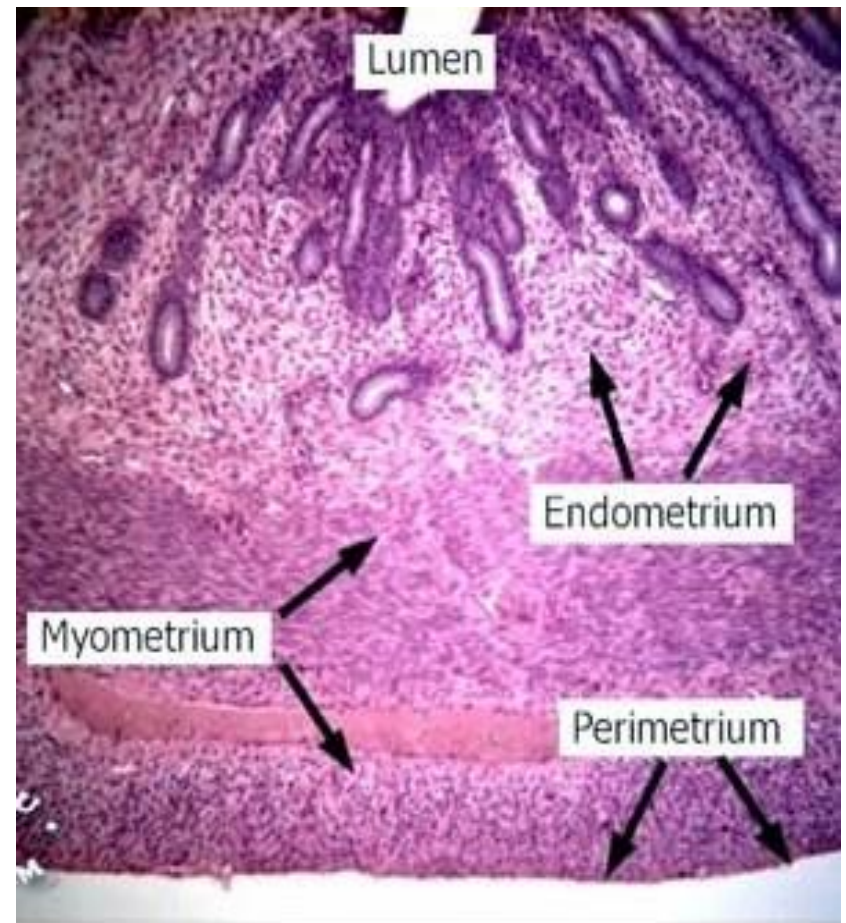
Uterine tube

- Tunica mucosa
- Lamina epithelialis
- Single row cylindrical epithelium composed of:
 - Cylindrical cells with cilia
 - Bright cytoplasm, poorly developed organelles, at the apical pole - kinocilia
 - Secretory cells
- Euchromatic core, organelles of the synthetic pathway, apical - microvilli.
- They synthesize glycoproteins
- Lamina propria
- Loose connective tissue
- Tunica muscularis
- Inner circular layer
- Outer longitudinal layer
- Corpus suseros – A layer of gridded binder
- Tunica serosa – Visceral peritoneum



Uterus

- Endometrium (tunica mucosa uteri)
- lamina epithelialis – single row cylindrical epithelium (ciliated and secretory cells)
- lamina propria contains gll. uterinae (epithelial folds - secretory cells)
- Stratum functionale – includes the upper $\frac{3}{4}$ of the endometrium.
- During the secretory phase, they are observed inside it
- stratum compactum and stratum spongiosum
- Stratum basale – the deepest, not subject to functional changes
- Myometrium (tunica muscularis)
 - -stratum submucosa
 - - stratum vasculare
 - - (stratum supravasculosum)
 - - stratum subserosum
- Perimetrium (Tunica Serosa)



Endometrium

- The endometrium, the mucous membrane that lines the uterus, is made of epithelium and lamina propria.
- The epithelium of the endometrium is single-row cylindrical.
- Secretory cylindrical cells and
- cylindrical cells with cilia.
- By sinking the epithelium into the lamina propria, which is located below, tubular uterine glands are formed, the epithelium of which consists only of secretory cells.
- The lamina propria or stroma of the endometrium consists of loose cellular connective tissue.
- It contains fibroblasts, rare lymphocytes, granulocytes and macrophages, a lot of basic substance, fibers, as well as uterine glands and blood vessels (spiral arterioles).

Endometrium

- According to the morphofunctional characteristics, the endometrium can be divided into two layers:
- Basal layer (stratum basale)
- The deepest layer of the endometrium (lower $\frac{1}{4}$) in which the bases of the uterine glands are located. It is not subject to cyclical changes, it serves as the basis for restoring the functional layer after menstruation, childbirth or abortion.
- Functional layer (stratum functionale)
- The thick superficial layer (upper $\frac{3}{4}$ of the endometrium) in which the bodies and necks of the uterine glands are located. It undergoes cyclical changes during the menstrual cycle and is shed during menstruation.
- The surface part of the functionalis contains the cervical parts of the uterine glands - st. compactum.
- Below it is a twice-thick part with glandular bodies - st. spongiosum.

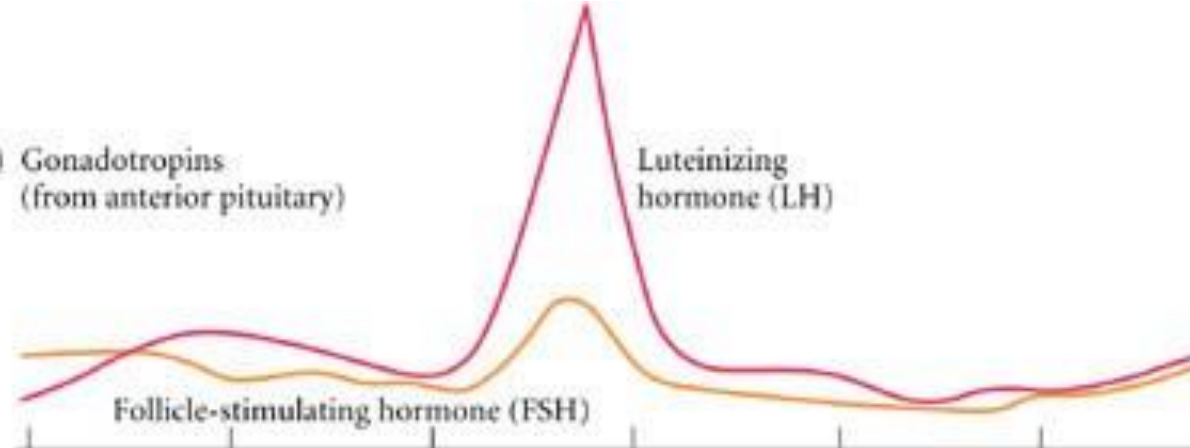
Myometrium

- The myometrium (tunica muscularis) is made up of smooth muscle cells that form three vaguely demarcated layers:
- Internal longitudinal layer - stratum submucosum
- In direct contact with the endometrium.
- Middle circular layer - stratum vasculare
- It contains large, thick-walled blood vessels.
- It has an important role in hemostasis after childbirth.
- Outer longitudinal layer – stratum subserosum
- Located under the perimetrium
- The perimetrium is the visceral layer of the peritoneum composed of mesothelium and a thin layer of loose connective tissue.
- It covers the back and part of the front surface of the uterus, the rest - adventitia.

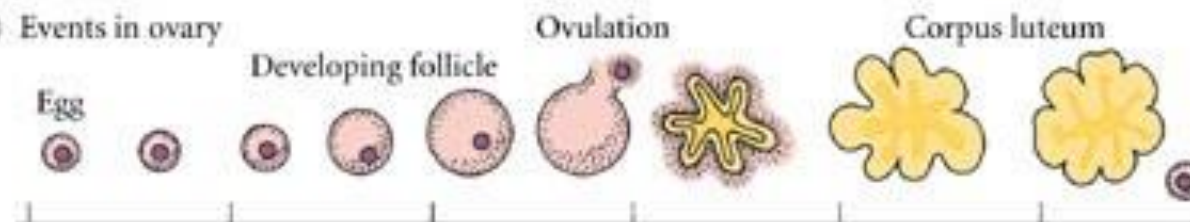
Menstrual cycle

- The menstrual cycle includes a series of morphofunctional changes of the endometrium that are periodically repeated under the influence of estrogen and progesterone.
- The cyclic nature of ovarian hormone secretion is determined by the cyclic production of gonadotropic hormones from the adenohypophysis (FSH and LH).
- The length of the cycle varies, but on average it is 28 days.
- There is no menstrual cycle before menarche, after menopause, as well as during pregnancy.
- The menstrual cycle begins on the first day of menstruation.
- The menstrual cycle can be divided into three phases: the menstrual phase, the proliferative (follicular) phase and the secretory (luteal) phase.


(A) Gonadotropins
(from anterior pituitary)



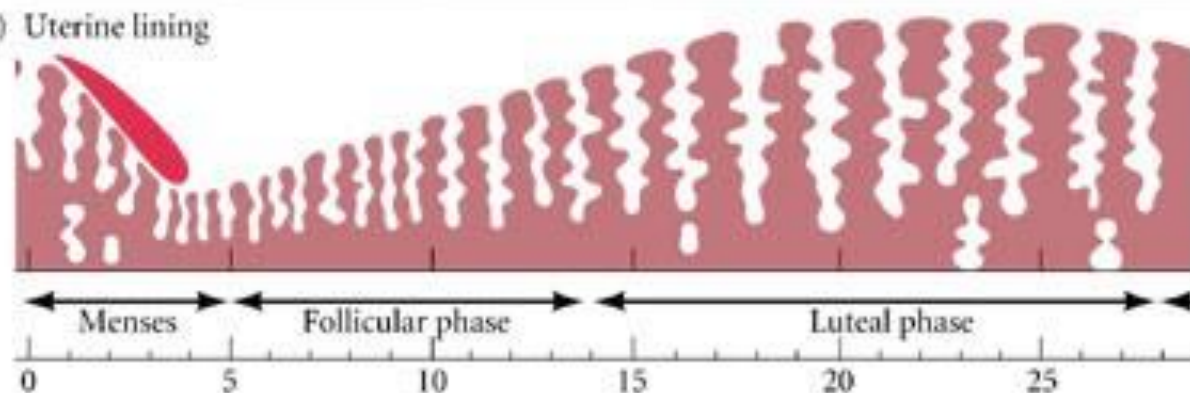
(B) Events in ovary



(C) Ovarian hormones



(D) Uterine lining



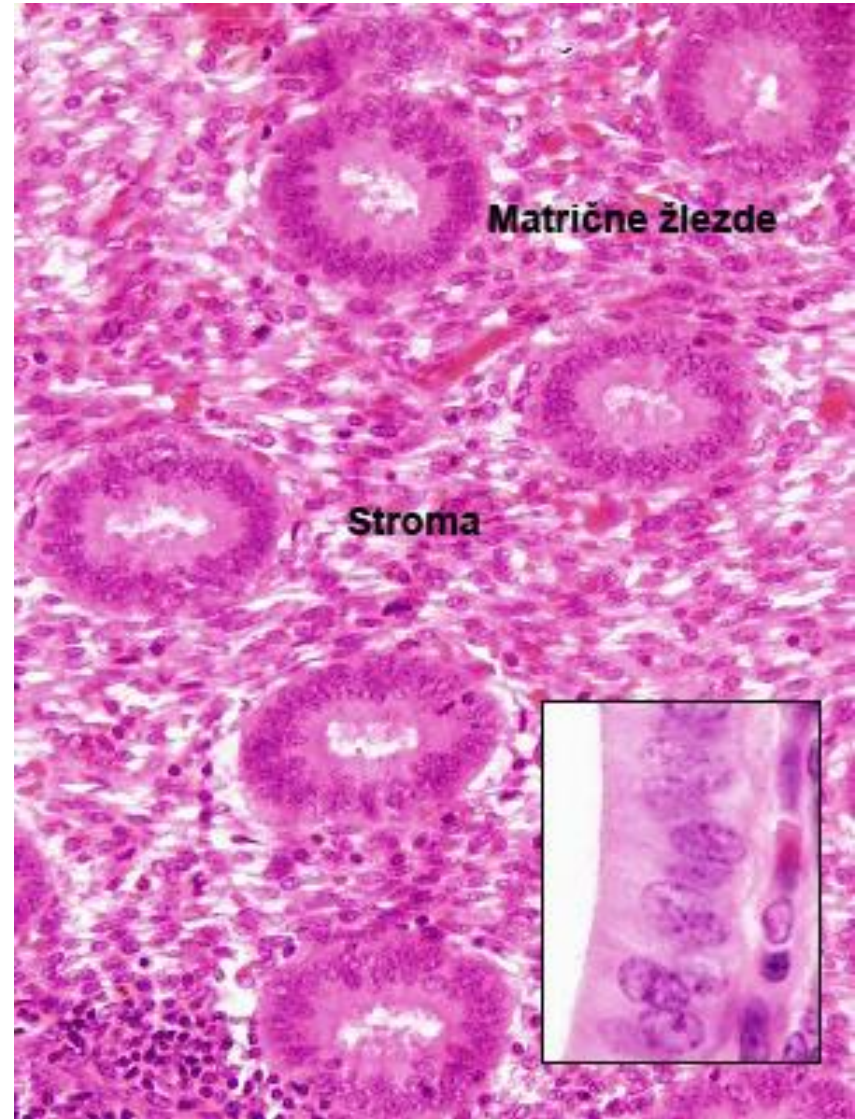
Day of menstrual cycle

Menstrual phase

- The menstrual phase includes the first five days of the menstrual cycle.
- It starts with the appearance of bleeding from the uterus every month, it always happens when fertilization does not occur.
- The first day of bleeding is the first day of the menstrual cycle.
- The menstrual phase is characterized by desquamation of the swollen functionalis.
- The changes are caused by the lack of progesterone due to spontaneous regression of the corpus luteum that occurs 10-12 days after ovulation.
- Although the entire functional part of the endometrium is shed, this process does not happen all at once, but continues continuously for 3-4 days.

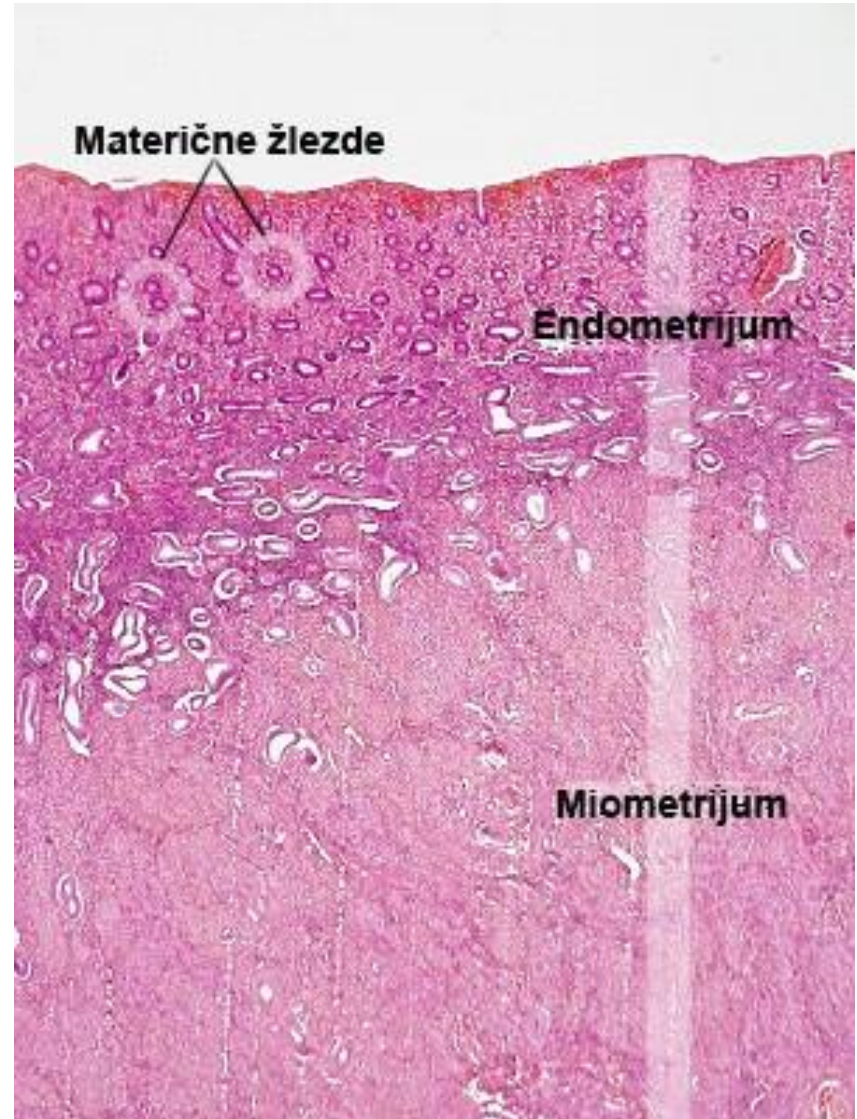
Proliferative phase

- The proliferative phase (estrogen or follicular phase) occurs at the same time as the maturation of the egg follicles (and the increasing secretion of estrogen).
- Starts 4-5. days of the menstrual cycle and lasts until ovulation.
- It is characterized by frequent mitoses of the residual epithelium at the bottom of the uterine glands and accelerated proliferation of stromal cells remaining in the basal layer.



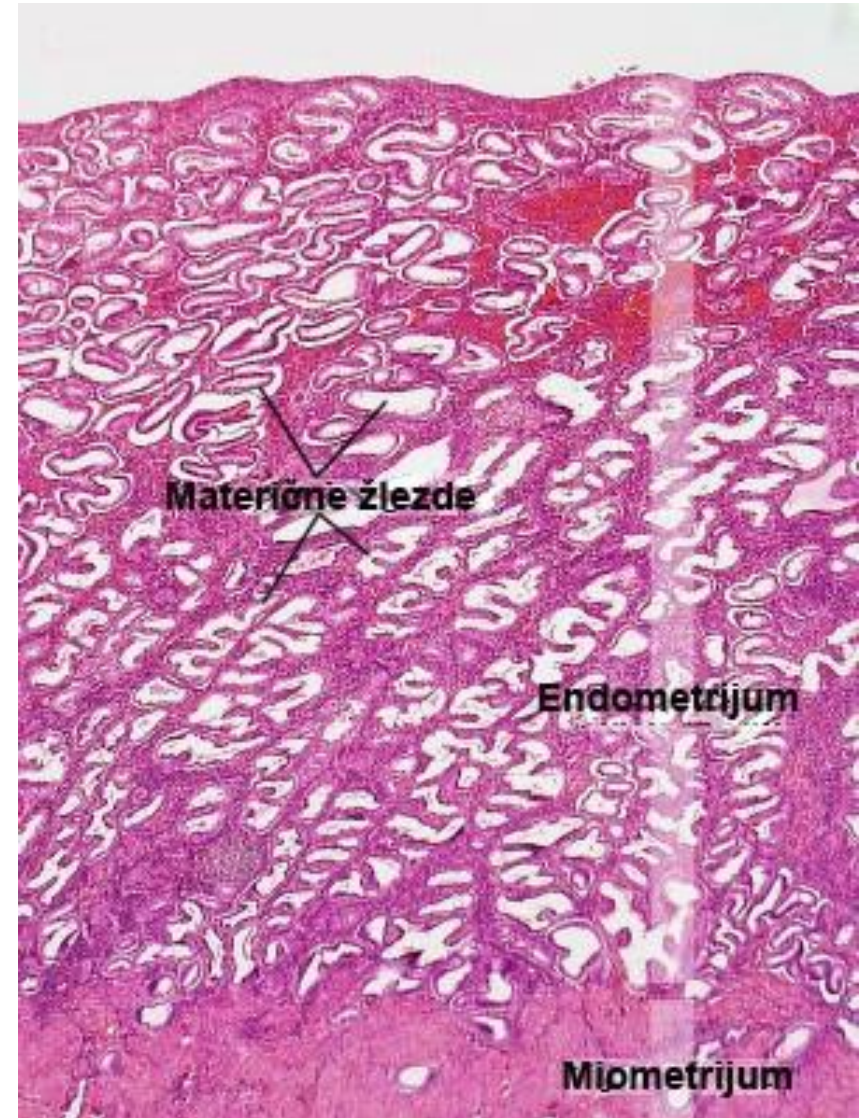
Proliferative phase

- During the proliferative phase, the functional layer of the endometrium is completely renewed, whereby it acquires its original appearance with a complete epithelium, glands, stroma and spiral arterioles.
- It has a variable length of duration - the individual difference in the length of the menstrual cycle is determined by the different length of the proliferative phase.



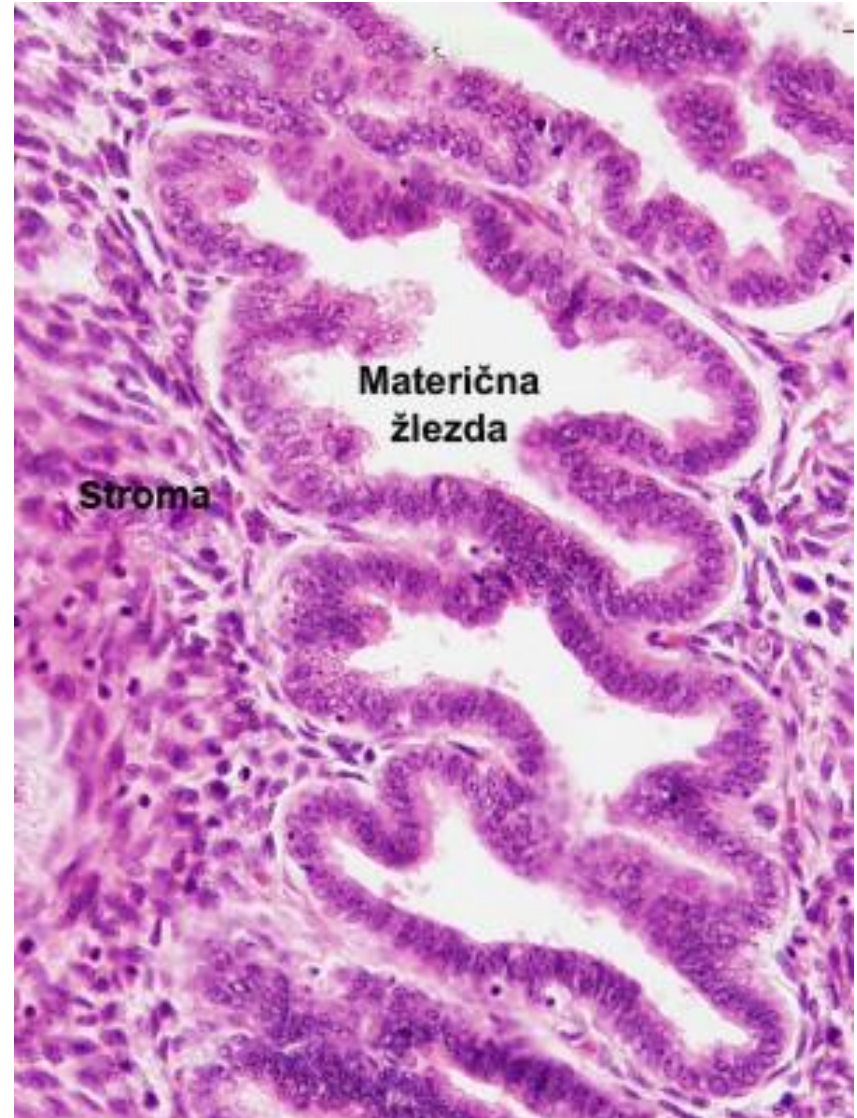
Secretory phase

- The secretory phase (progesterone, progestin or luteal phase) begins after ovulation with the effect of corpus luteum progesterone on the previously restored functional layer of the endometrium.
- This phase is stable in time and lasts 14 days - it takes place from ovulation to the next menstruation.
- The secretory phase is divided into wound and the late secretory phase.



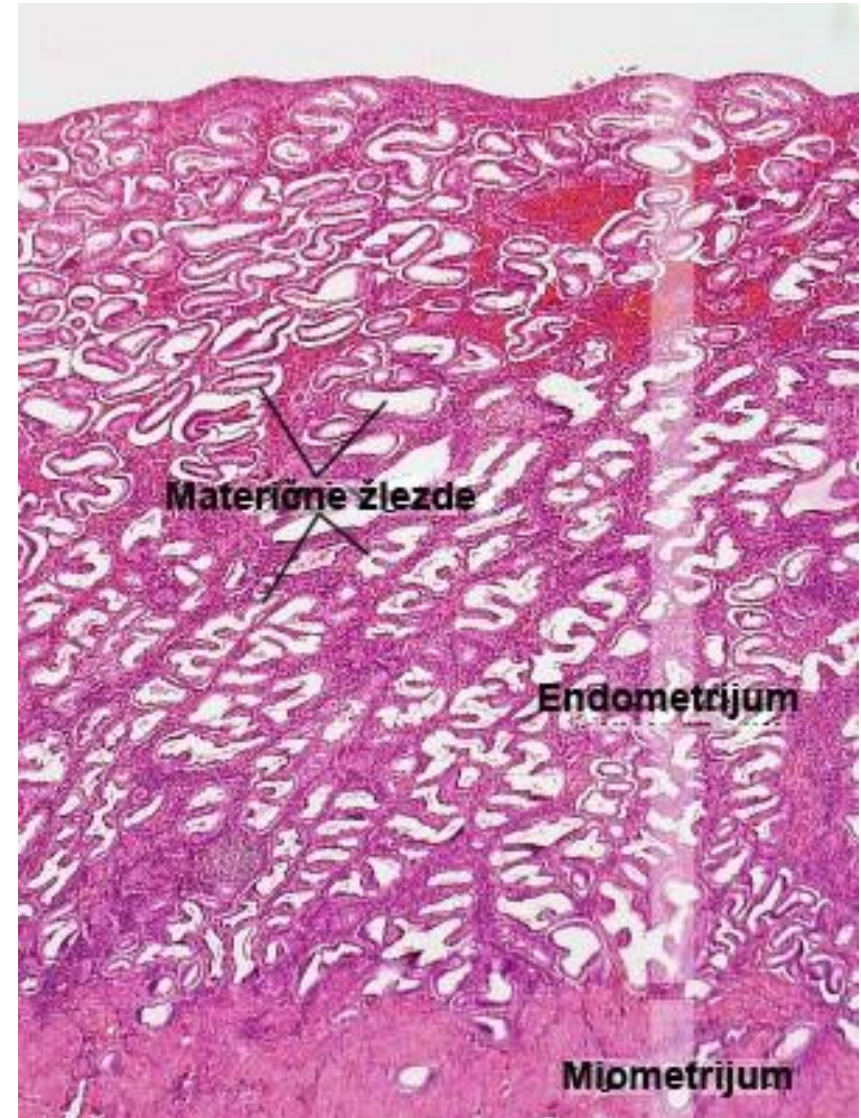
Secretory phase

- In the early secretory phase, glycogen particles are deposited in the basal part of the cytoplasm of the secretory cells in the composition of the endometrial glands.
- This glycogen-rich secretion is intended to nourish the fetus until the placenta forms.
- Uterine glands are elongated, their lumen is filled with secretion and expands.



Secretory phase

- Spiral arterioles reach their maximum length (branches reach near the surface of the endometrium)
- The abundance of secretions and edematous stroma provide an optimal substrate for blastocyst implantation.
- At the end of the secretory phase, the endometrium is ready to accept and nourish the embryo in the period preceding the formation of the placenta.

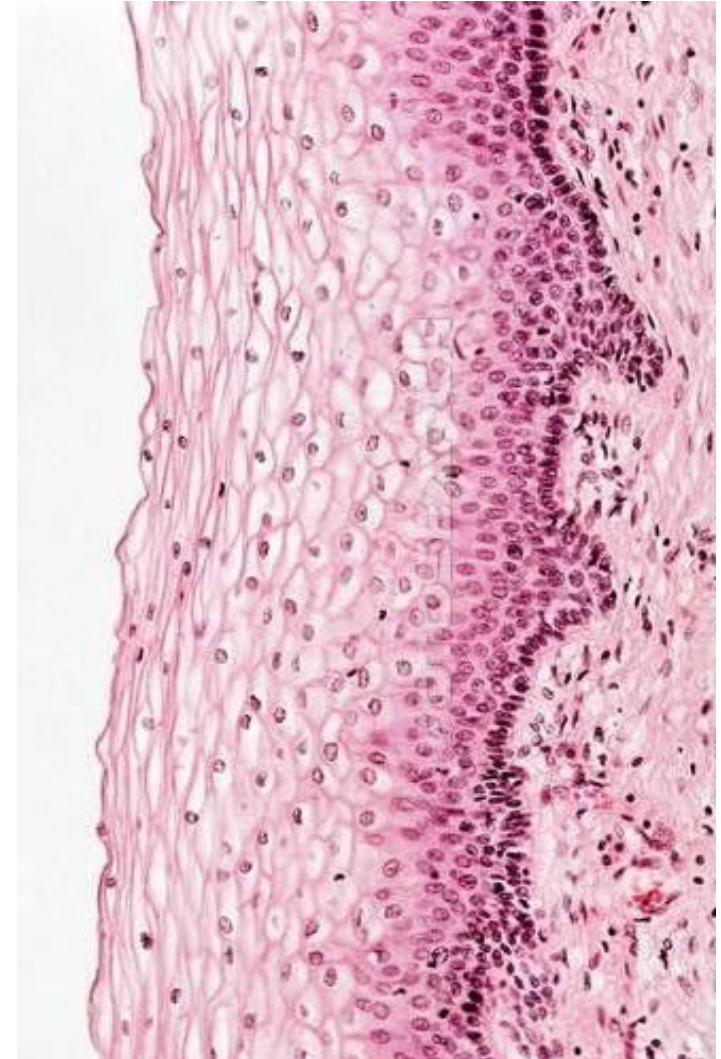

Secretory phase

- If the blastocyst implants in the uterine wall, the endometrium thickens even more and the secretory phase transitions to the pregnant phase.
- In that case, a large amount of progesterone is secreted from the gravid corpus luteum and trophoblast of the placenta, under the influence of which the endometrium transforms into three types of decidua:
 - Decidua basalis
 - Decidua parietalis
 - Decidua capsularis
- If implantation is absent, the endometrium passes into the menstrual phase of the cycle.

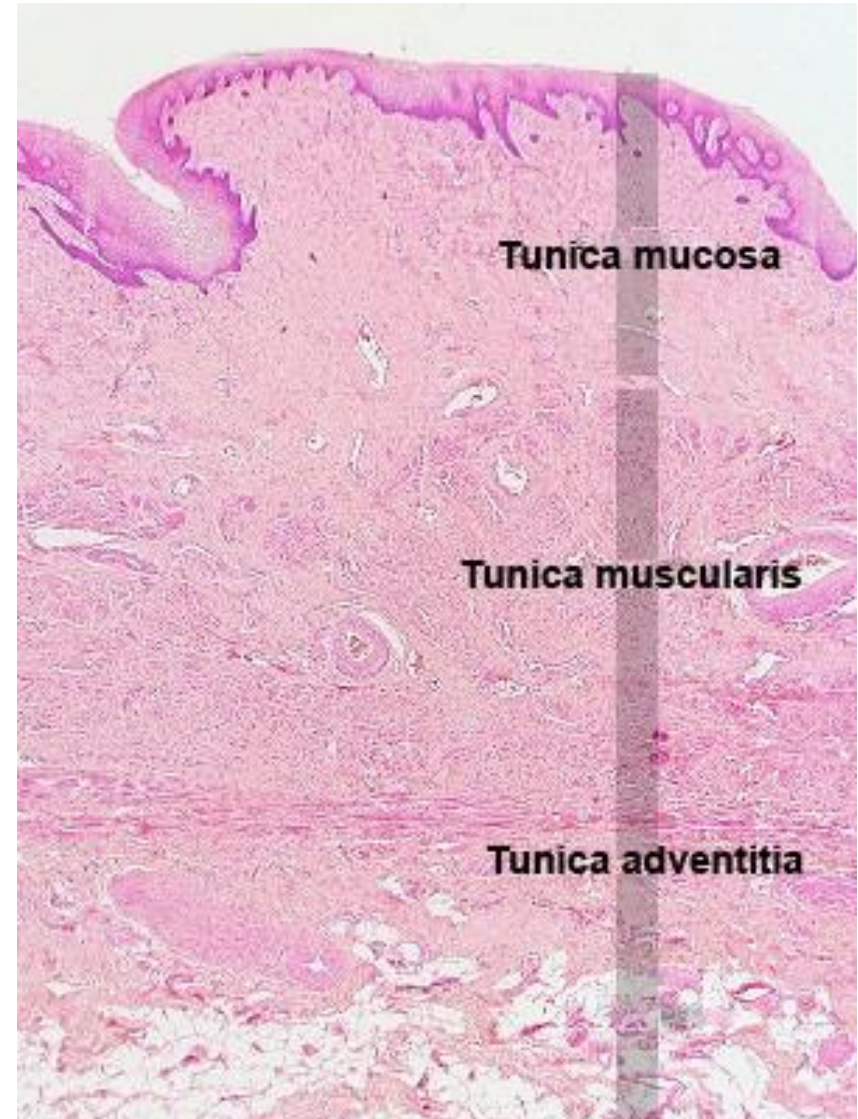
Cervix uteri

- Portio vaginalis uteri (PVU) –
- The distal part of the cervix that enters the vagina, covered by the ectocervix.
- The entire length of the cervix - canalis cervicis
- lined by the endocervix
- The wall of the cervix consists of three layers:
- Tunica mucosa
- Lamina epithelialis
- Ectocervix – plate-layered without armoring
- Endocervix – single-layer cylindrical (bright secretory cells and cylindrical cells with kinocilia)
- Between them – a squamocylindrical border
- Cervical glands
- Lamina propria
- Myometrium
- Weakly developed, does not contain myocytes
- Perimetrium
- (t. serosa from the back; t. adventitia from the front)



Vagina

- Tunica mucosa
- Lamina epithelialis
- Squamous epithelium without armature.
- Contains Langerhans cells.
- Lamina propria
- Superficial layer - cellular connective tissue
- Deep layer – loose connective tissue with a lot of elastic bundles.
- Contains thin-walled veins ("erectile bodies")
- No glands
- Tunica muscularis
- Inner circular layer Outer longitudinal layer
- Tunica adventitia
- Loose connective tissue



External genitalia

- Mons pubis – a mass of fatty tissue covered by skin.
- Labia majora – paired skin folds analogous to the scrotum in men.
- The outer side contains hair follicles, while on the inner side they are absent.
- They contain merocrine and apocrine sweat, as well as sebaceous glands.
- Labia minora – folds of pigmented skin without hair and fatty tissue, analogous to the skin of the penis.
- In the lamina propria there is a spongy connective tissue with a lot of elastic fibers, blood vessels and sebaceous glands.
- Vestibulum vaginae – the vestibule opens into the urethra, vagina and outlet
- ducts of the vestibular glands that produce mucous secretions.
- In the lateral wall there are paired, tubuloalveolar cells. vestibulares majores
- (Bartholin's glands).
- Around the opening of the urethra and near the clitoris there are gl. vestibulares minores
- Clitoris – analogous to the penis in men.
- It contains two cavernous bodies surrounded by fibrous connective tissue.
- In the front part, they are joined in a rudimentary glans clitoridis covered by an incomplete foreskin.
- It is covered with thin skin without hair, sweaty and sebaceous glands; quite sensitive n. fibers.

URINARY SYSTEM

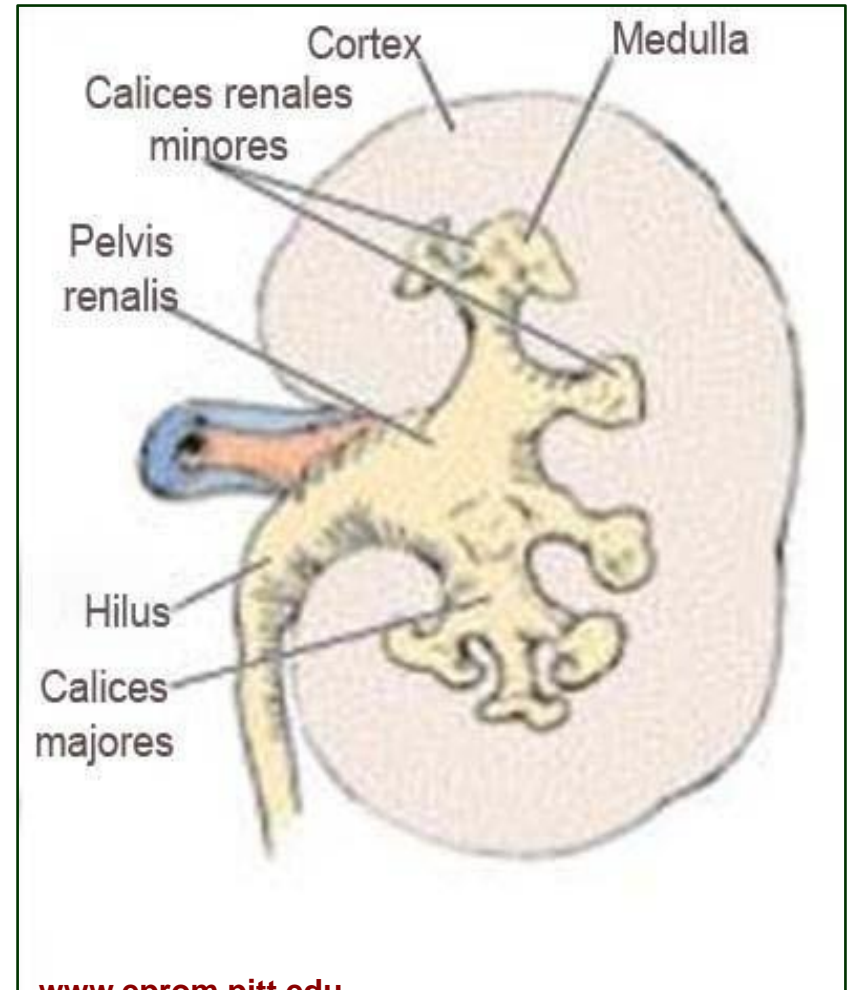
Urinary system

- The urinary (uopoiesis) system consists of:
- Kidneys
- Ureters
- Urinary bladder
- Urethral tube
- They produce and excrete urine and thereby:
- They remove excess water and electrolytes from the body
- Expel toxic metabolic products (urea and creatinine)
- They regulate the volume and composition of body fluids
- They regulate the acid-base balance
- They stabilize blood pressure
- In addition to uopoiesis, the kidneys also have an endocrine function
- renin, erythropoietin, prostaglandins, D3 vitamin activation

Kidney

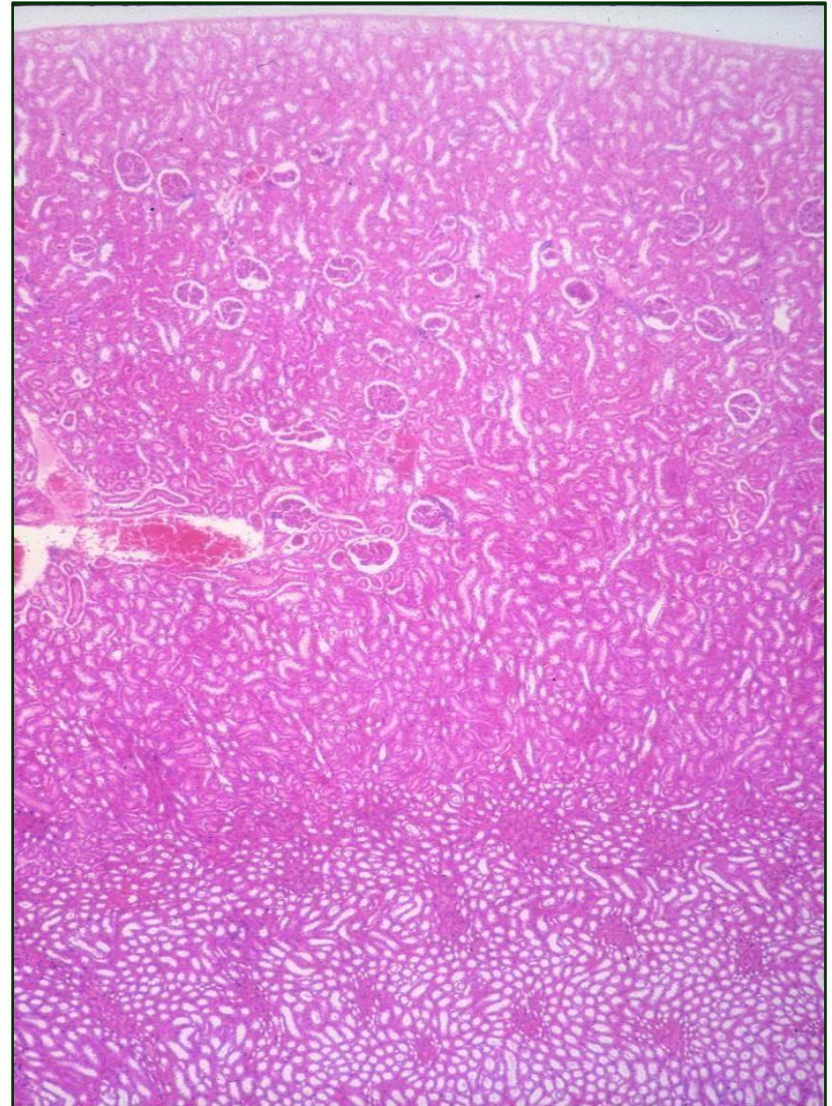
Kidney

- Kidneys are central organs
- urinary system
- The outer side of the kidney is convex, and the inner, concave side has a hilus
- The renal artery and nerves enter and leave the kidney through the hilus
- ureter, renal vein and lymphatic vessels



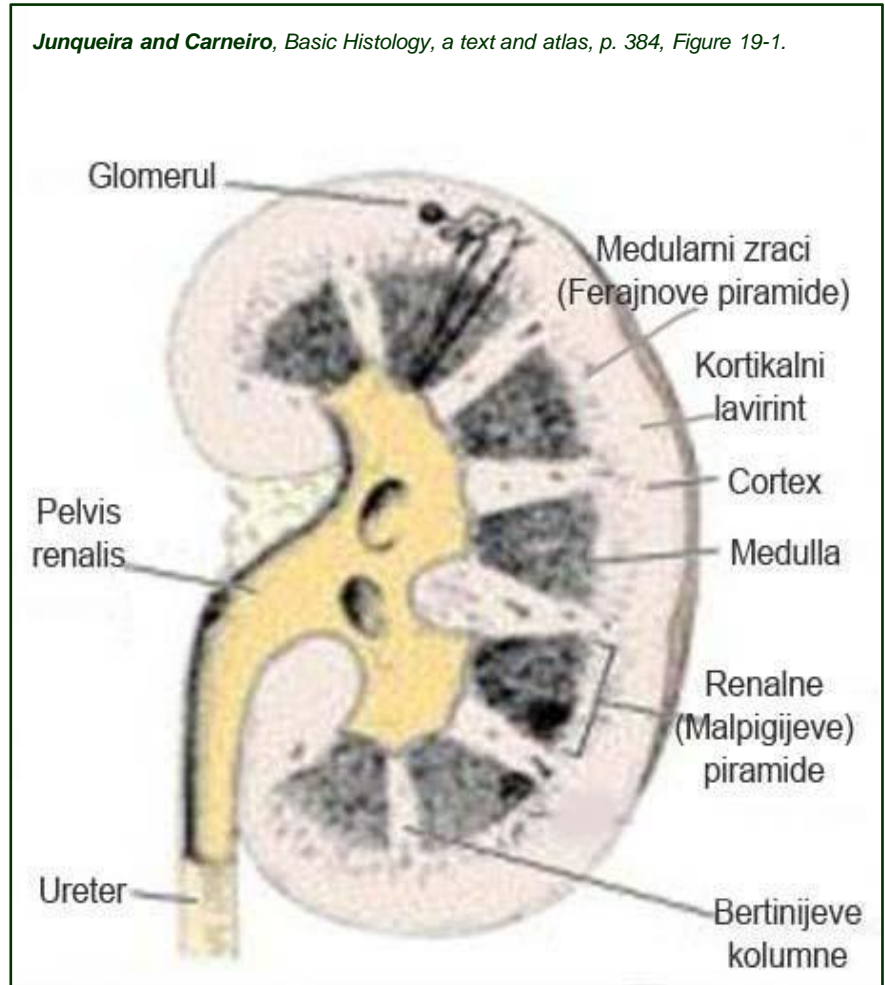
Kidney

- The structure of the kidney consists of parenchyma and stroma
- The parenchyma consists of a large number of tubules that are in close connection with the capillary network at the beginning, while at the other end they open into the renal calyces.
- The parenchyma is divided into:
 - Cortex – peripheral zone
 - Medulla – the inner zone
- The stroma consists of:
 - Capsule - a two-layer covering of the kidney
 - Interstitial binder - scarce
 - loose tissue



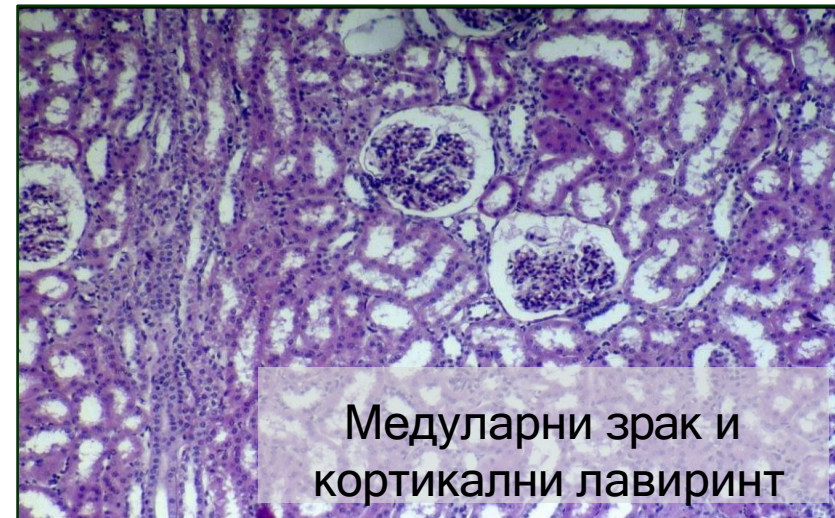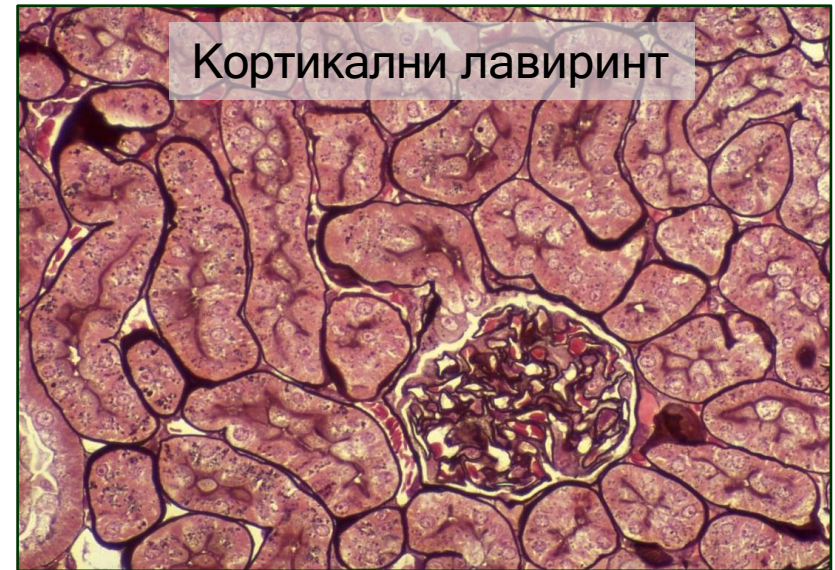Medulla

- The medulla consists of 10-18 renal (Malpighian) pyramids
 - The base of the pyramid at the border of the medulla and the cortex.
 - The top of the pyramid - the renal papilla - enters the small renal calyx.
 - Large renal lobes - renal pelvis - beginning of the ureter.
- **Renal (Bertini) columns**
 - Between the renal pyramids.
 - They represent part of the cortex in
 - medulla.



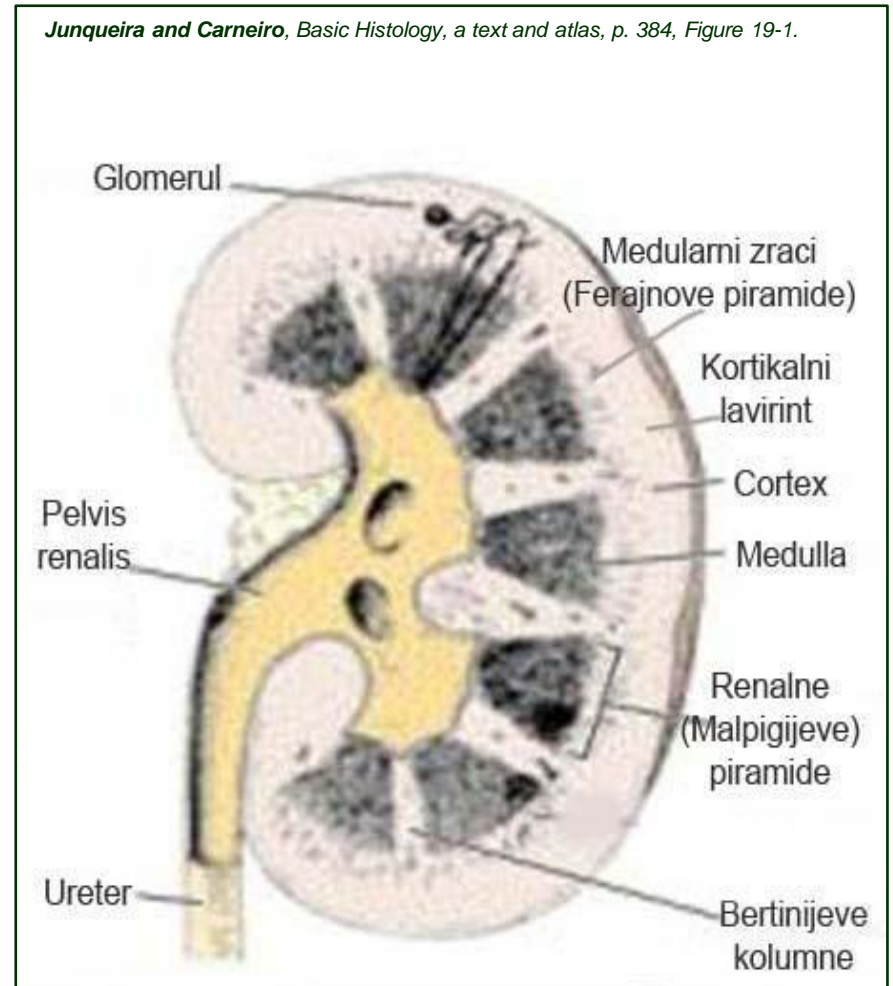
Cortex

- The cortical (renal) labyrinth is located between the medullary rays and represents the true cortical substance
- Medullary rays (Ferainov pyramids)
 - They represent part of the medulla in the cortex.
 - They are projected from the bases of the renal pyramids into the cortex.
 - From one pyramid 400-500 medullary rays.
- Cortical cortex
 - Narrow subcapsular zone that does not contain renal corpuscles.



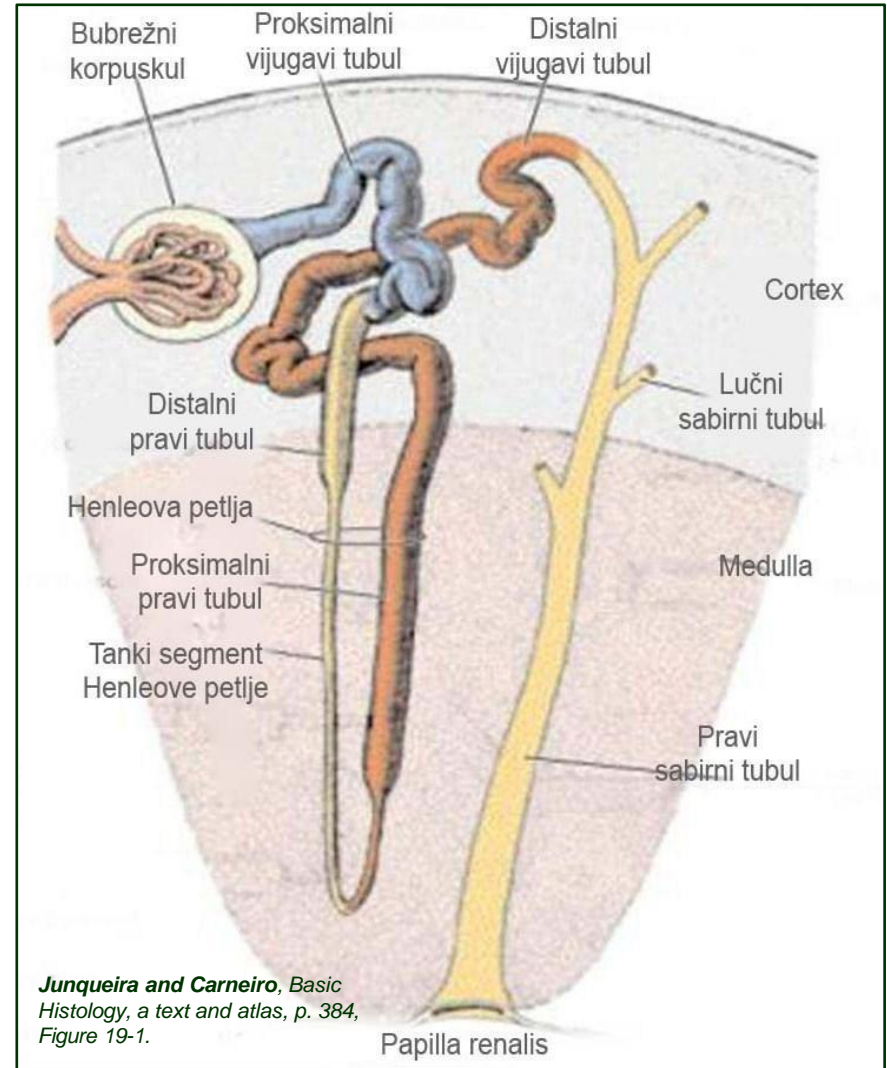
Renal lobe and renal lobule

- The kidney can be divided into smaller morphological units - lobes and lobules
- The renal lobe is formed by:
 - Renal (Malpighian) pyramid
 - Cortical substance above its bases
 - Half of the neighbors
 - Bertini columns
- The renal lobule consists of:
 - One medullary ray
 - Parts of the cortical labyrinth that immediately surround it



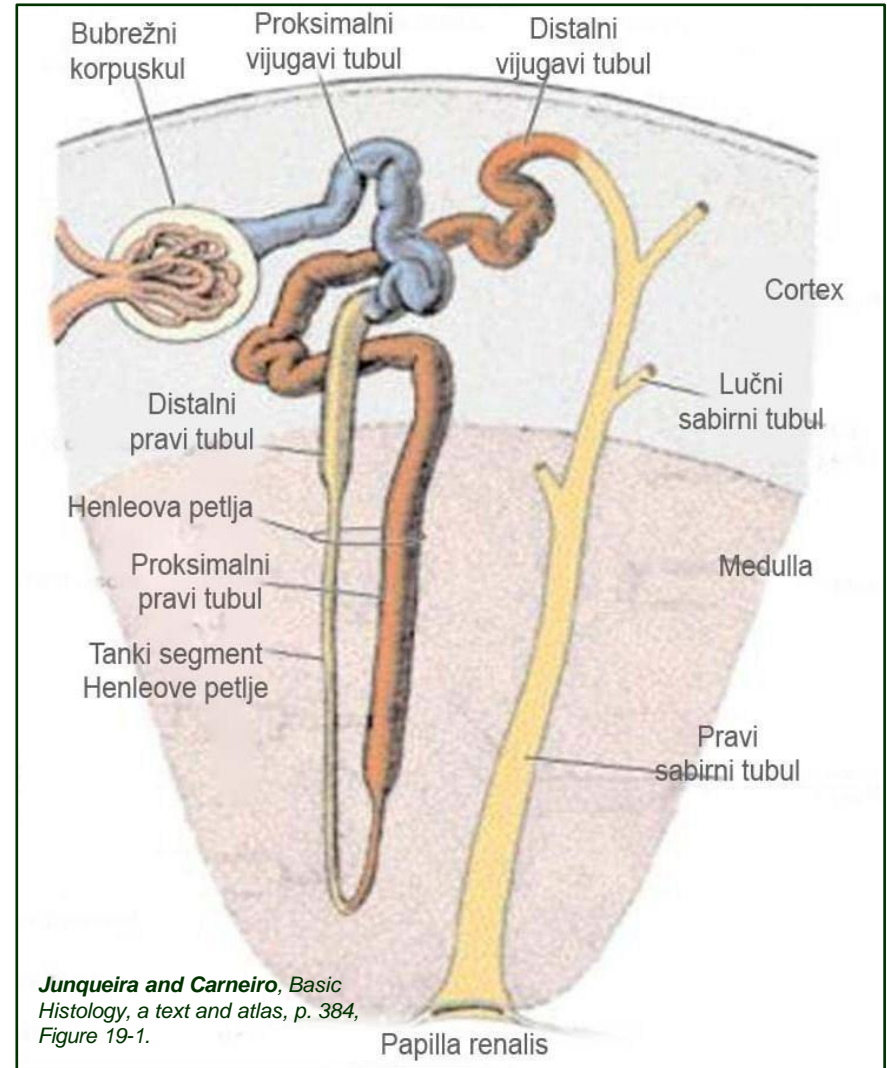
Nephron

- The basic morphofunctional unit of the kidney
- A nephron forms a renal corpuscle and renal tubule
- The renal corpuscle is initial, spherical part of the nephron and consists of:
 - Bowman's capsule
 - Renal glomerulus



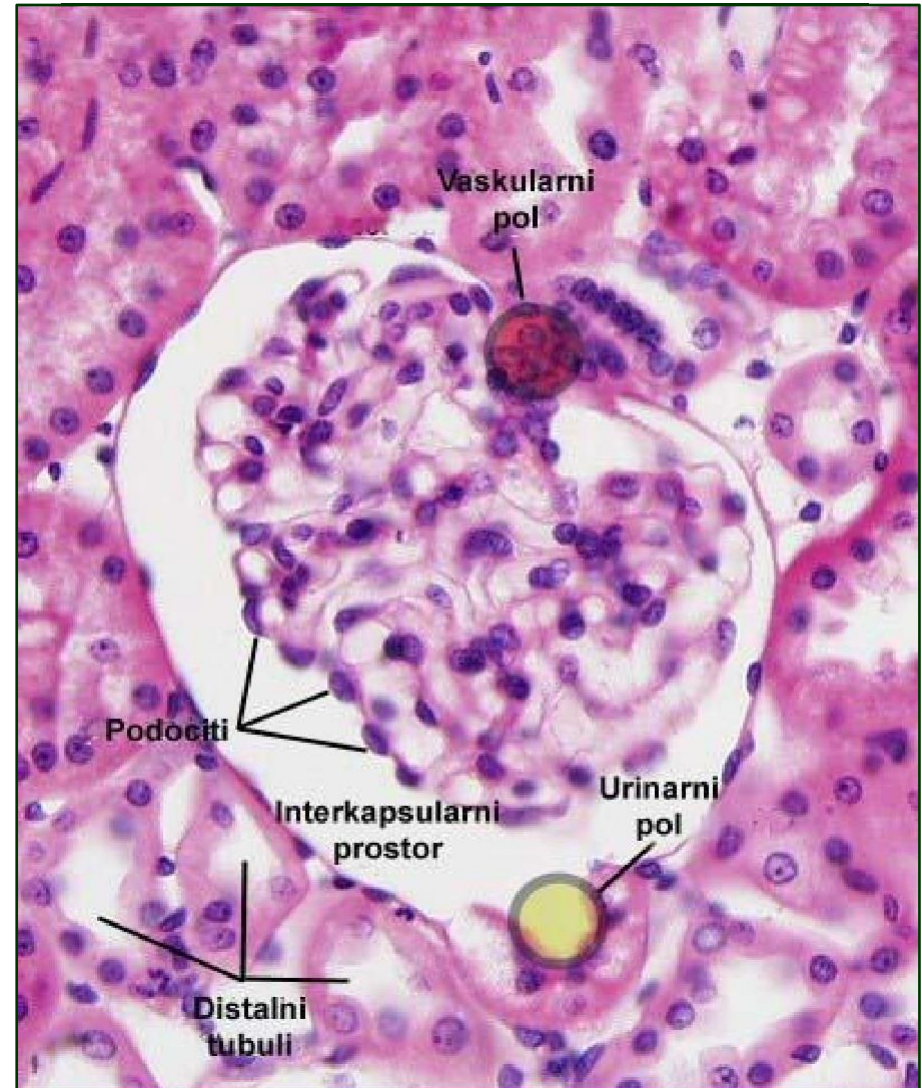
Nephron

- The renal tubule is a tubular part of the nephron that consists of several segments:
 - Proximal convoluted tubule
 - Proximal straight tubule
 - Thin segment of Henle
 - loops
 - Distal straight tubule
 - Distal convoluted tubule



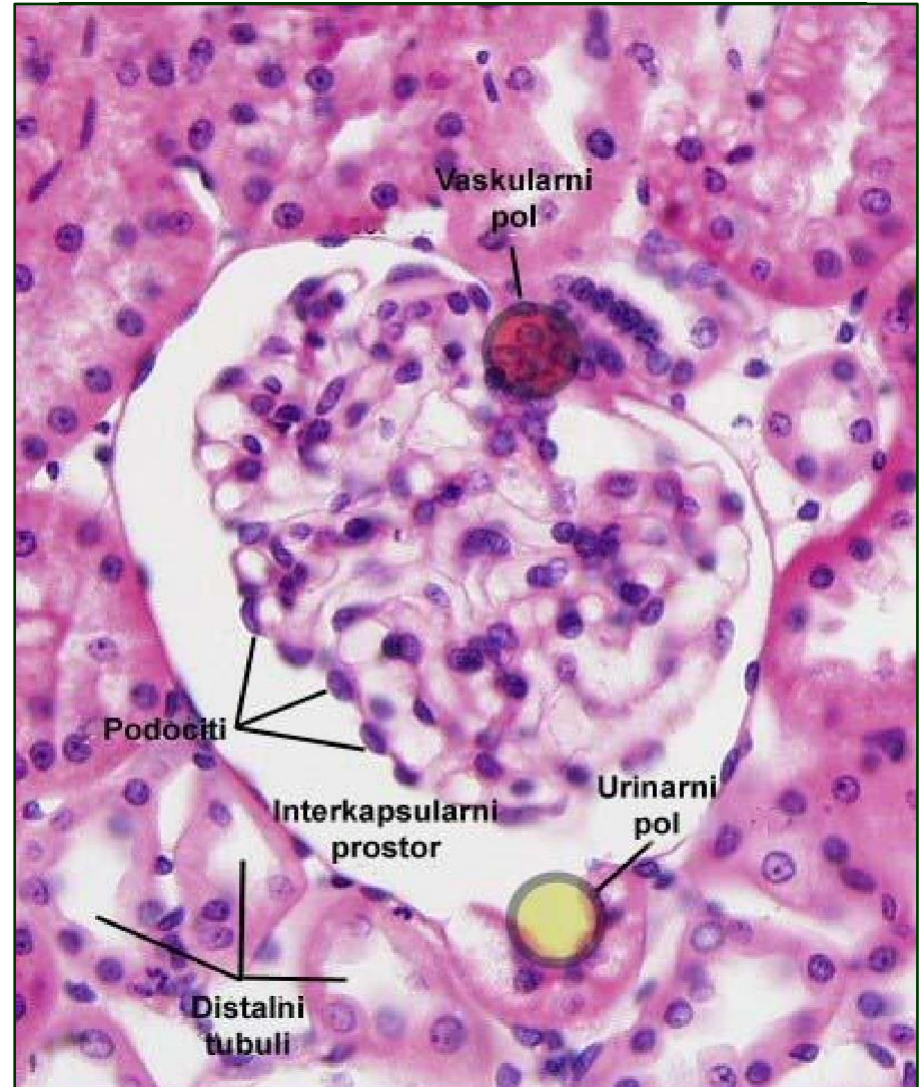
Renal corpuscle

- The renal corpuscle is the initial, enlarged part of the nephron in which blood plasma is filtered and primary urine is produced
- It consists of the renal glomerulus and Bowman's membrane



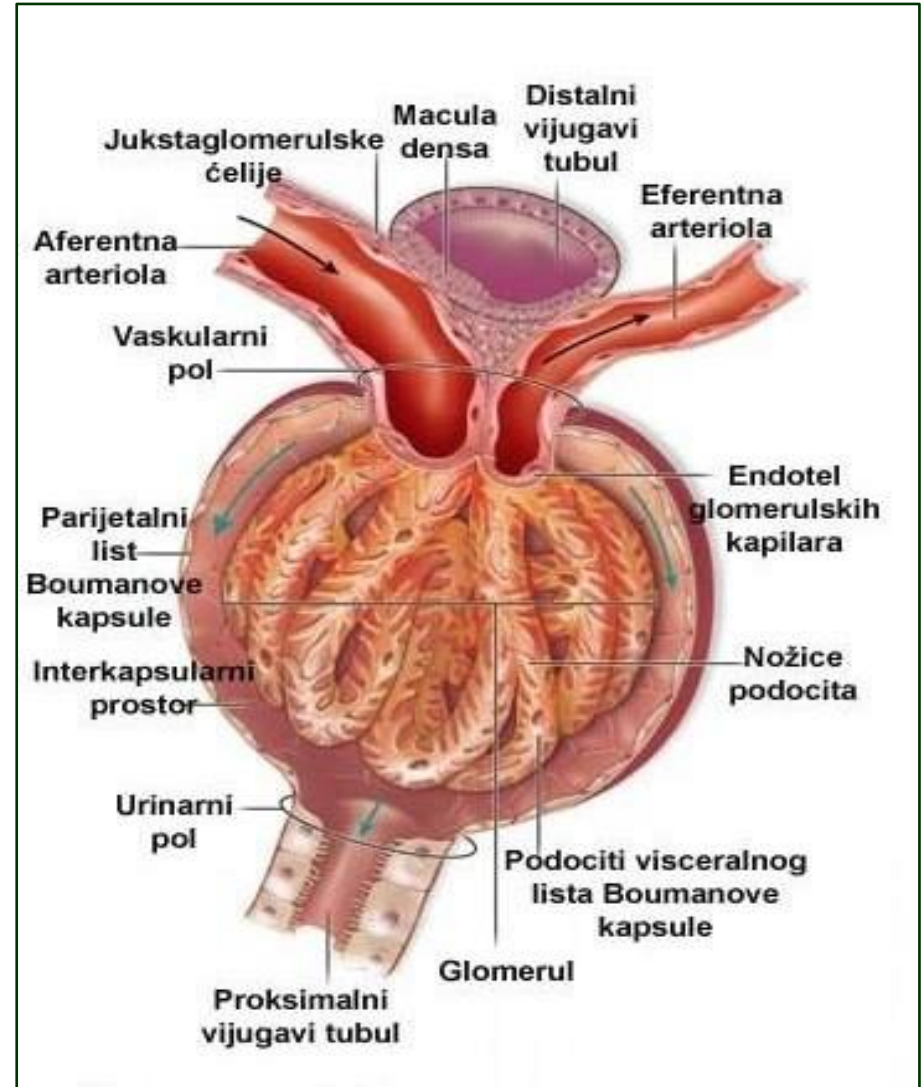
Renal corpuscle

- Renal glomerulus is a complex of densely packed fenestrated capillary that connects the afferent and efferent arteriole
- On it we distinguish:
 - Vascular pole - approach of the supply (afferent) arteriole
 - Urinary pole - filtered plasma (primary urine) is drained from the corpuscles



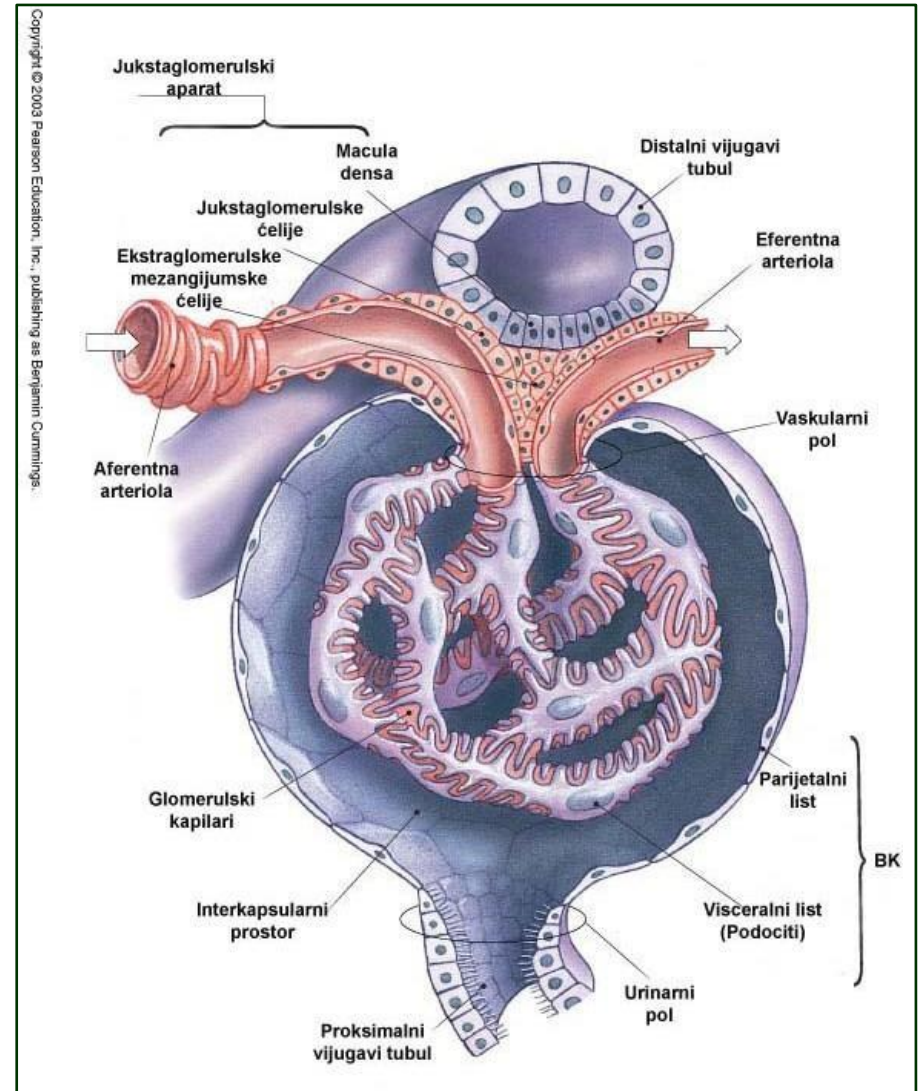
Renal corpuscle

- Bowman's capsule is a double epithelial lining that surrounds the glomerulus
- They are:
- Outer (parietal sheet) - single-row squamous epithelium
- Internal (visceral sheet) - podocytes that enclose the capillary with foot-like extensions
- Between the two leaves of Bowman's capsule there is an intercapsular (urinary, Bowman's) space.



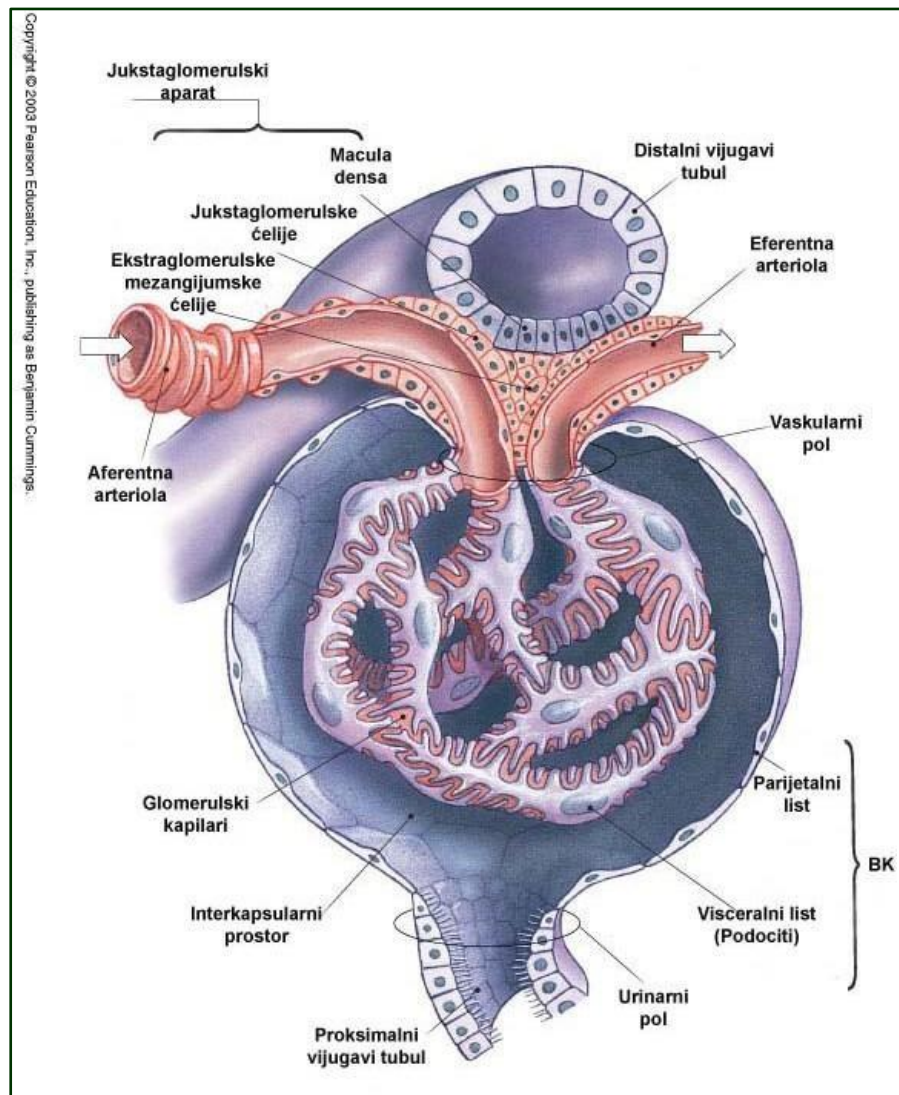
Filtration barrier

- It is a filtration barrier
- semipermeable biological
- the membrane that lies between
- capillary and urinary lumen
- space
- Filtration of blood when passing through the capillary tube results in blood ultrafiltrate (primary urine).



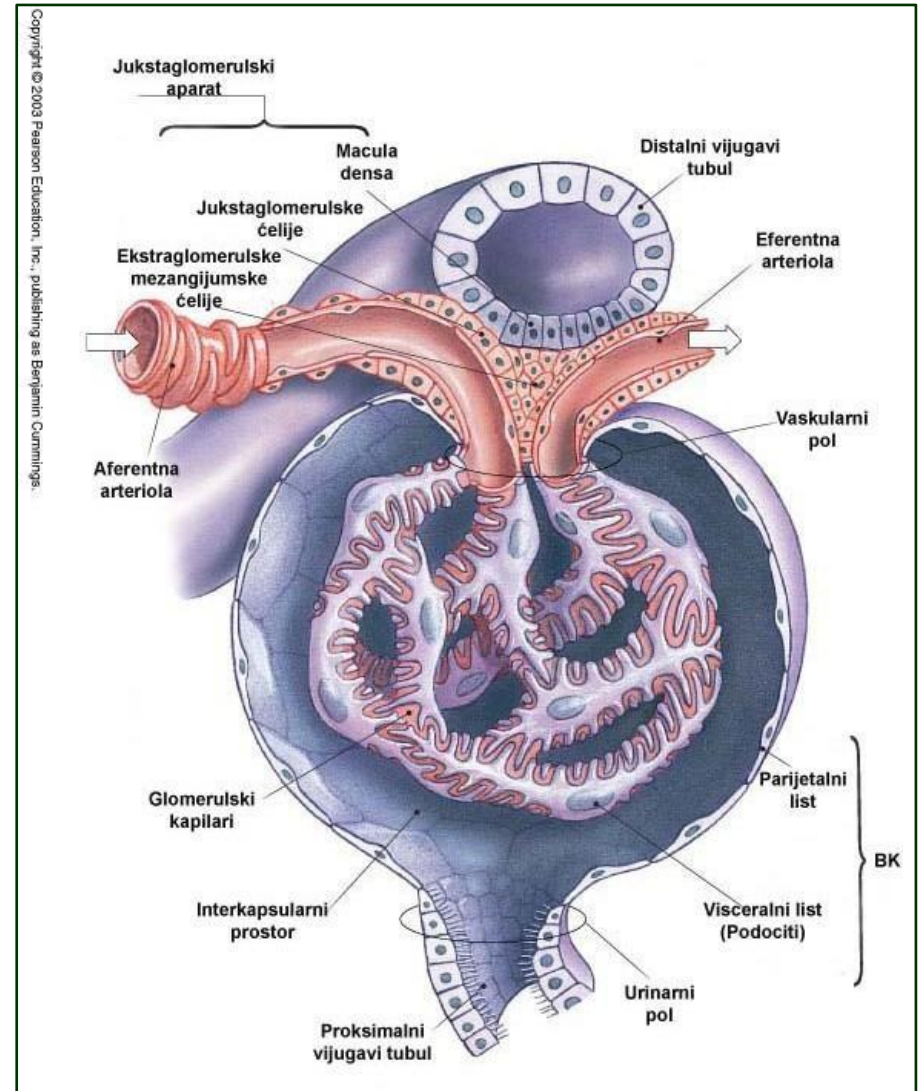
Filtration barrier

- The composition of the filtration barrier includes three components:
- capillary endothelium
- glomerular basement membrane (GMB) formed by fusion of basal laminae of endothelium and podocytes
- membrane of filtration cracks of podocytes



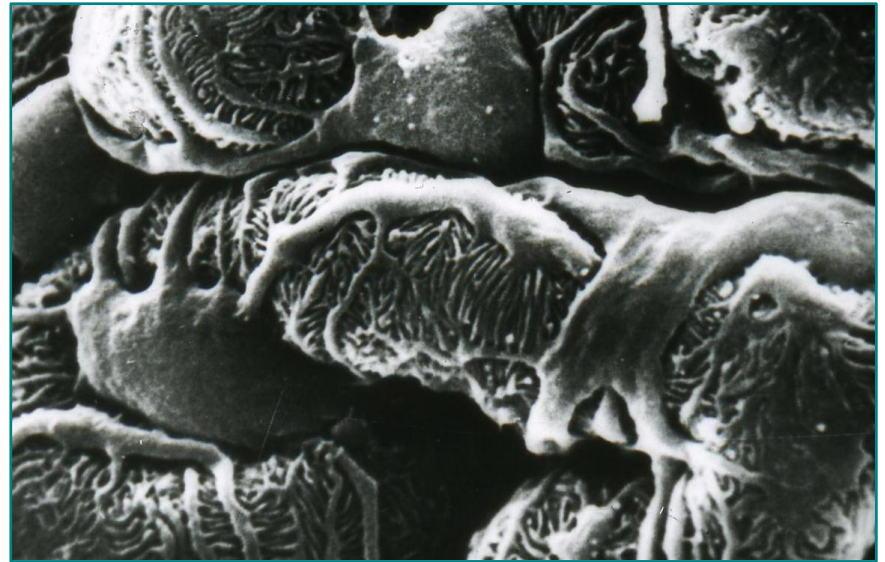
Glomerular basement membrane

- It is formed by the fusion of the basal lamina of capillary endothelial cells and the basal lamina
- podocytes
- It has a trilaminar structure:
 - Lamina rara interna
 - Lamina densa
 - Lamina rara externa
- Light layers - laminin,
- fibronectin and heparan sulfate.
- Dense layer - collagen IV



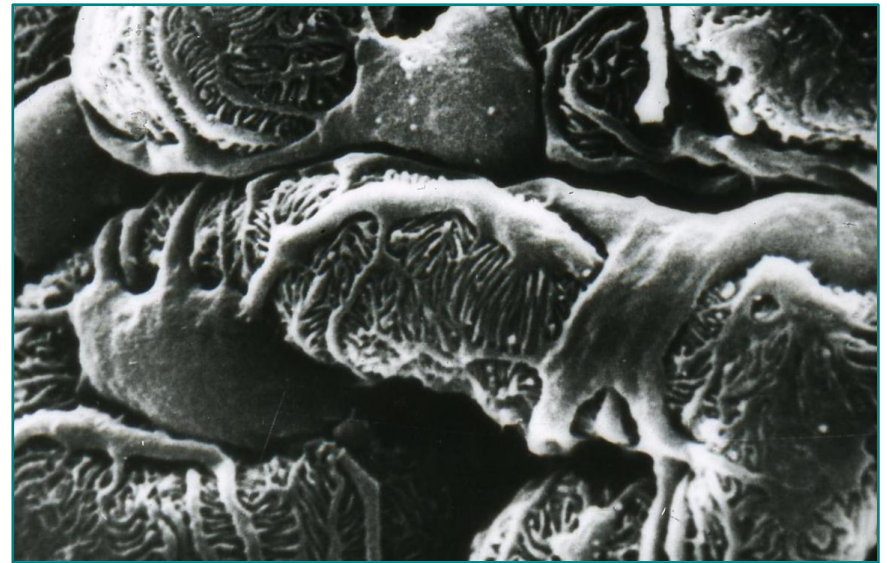
Membrane of filtration slits of podocytes

- The third component of filtration barriers.
- They are made by extensions of podocytes.
- Podocytes control the degree of permeability of the filtration barrier.
- Podocyte damage - proteinuria.
- Podocyte bodies are located in the visceral sheet of Bowman's capsule.



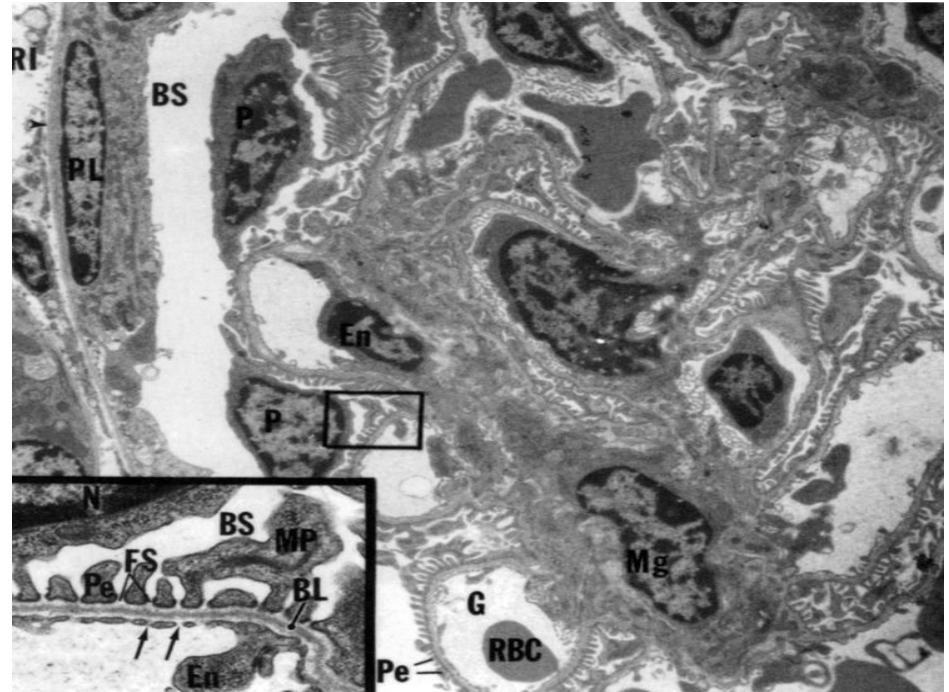
Podocytes

- Specialized epithelial cells with three generations of extensions
- They give off several long primary extensions parallel to the capillary axis
- Primary extensions branch to secondary, secondary to finger-shaped tertiary
- Secondary and tertiary adhere to the GBM and are called legs (pedicles)



Mesangial cells

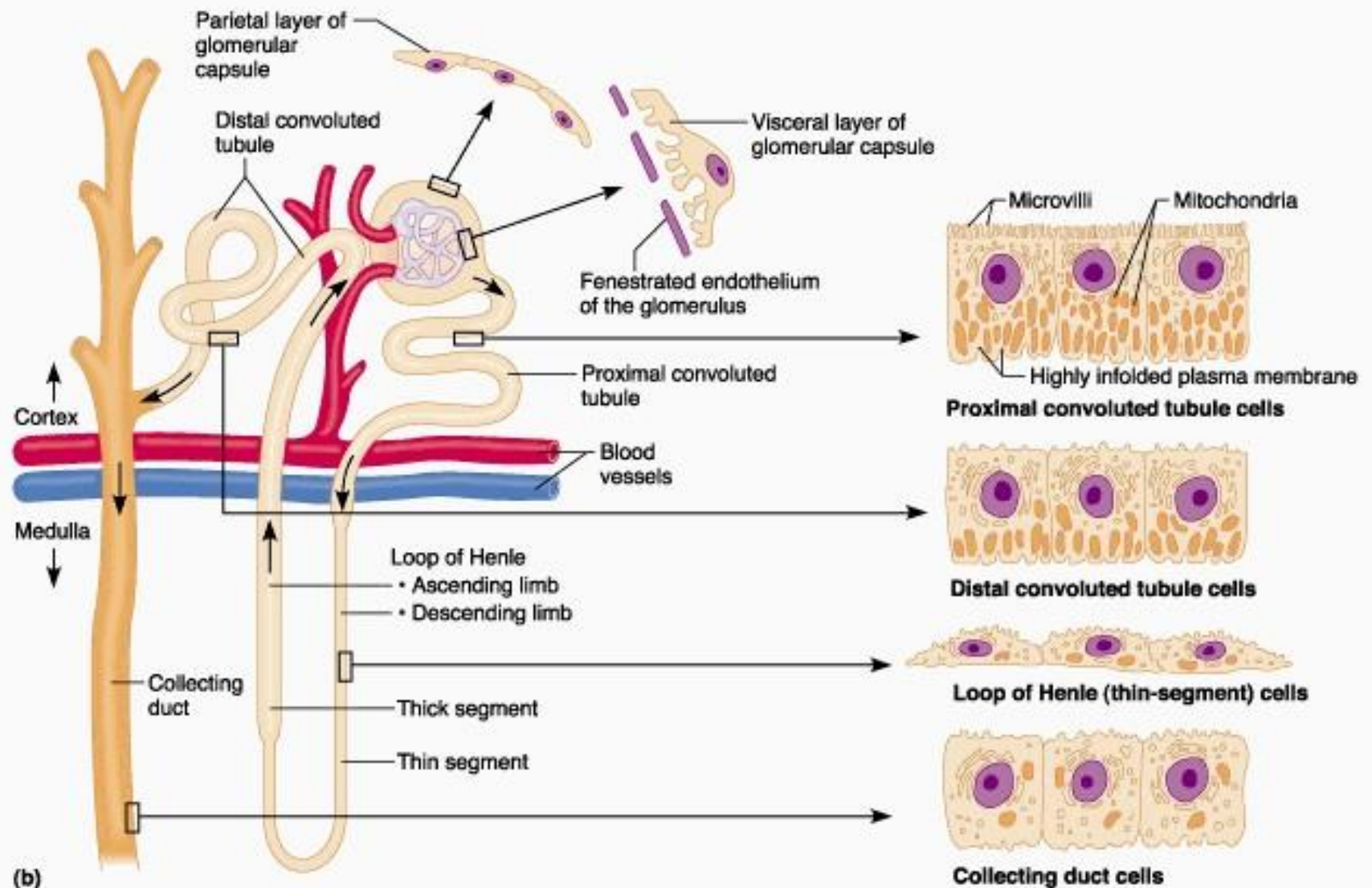
- The space between the glomerular capillaries is filled with mesangium.
- The mesangium consists of mesangial cells and the mesangial matrix created by the cells.
- Intraglomerular and extraglomerular mesangial cells.



Renal tubule

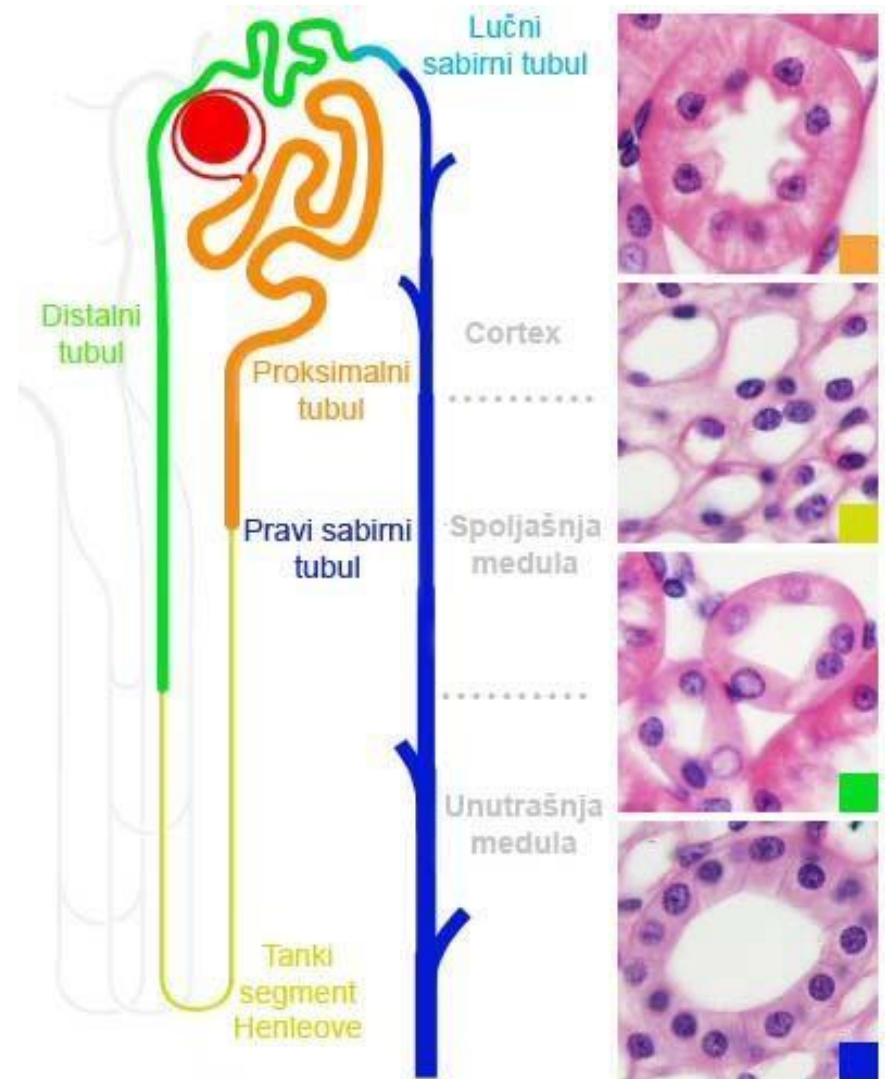
- The renal tubule extends from the urinary pole of the renal corpuscle to the arcuate collecting tubule
- It is lined with a single-layered epithelium throughout, but the cells in its individual segments differ in shape and ultrastructure
- The main function of tubules is the reabsorption of water, electrolytes and other constituents of glomerular filtrate
- The tubule has three histophysiological zones
- The proximal and distal tubule segments have a tortuous course; they connect the right part of the tubule (Henle's loop) which has a descending and ascending branch

Renal tubule



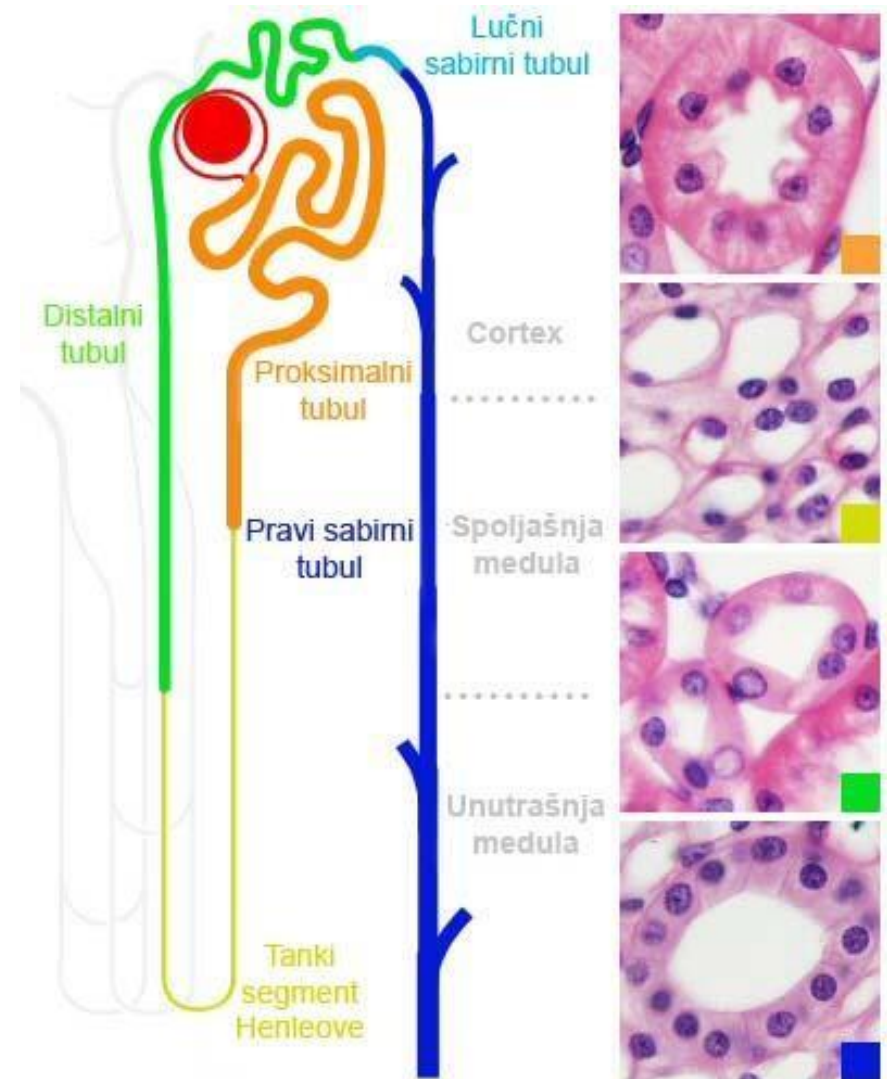
Renal tubule epithelium

- Proximal convoluted tubule
- Single row squamous epithelium
- Proximal nephrocytes with microvilli – brushy cover
- Proximal straight tubule (prox. thick segment HP)
- Single row squamous epithelium



Renal tubule epithelium

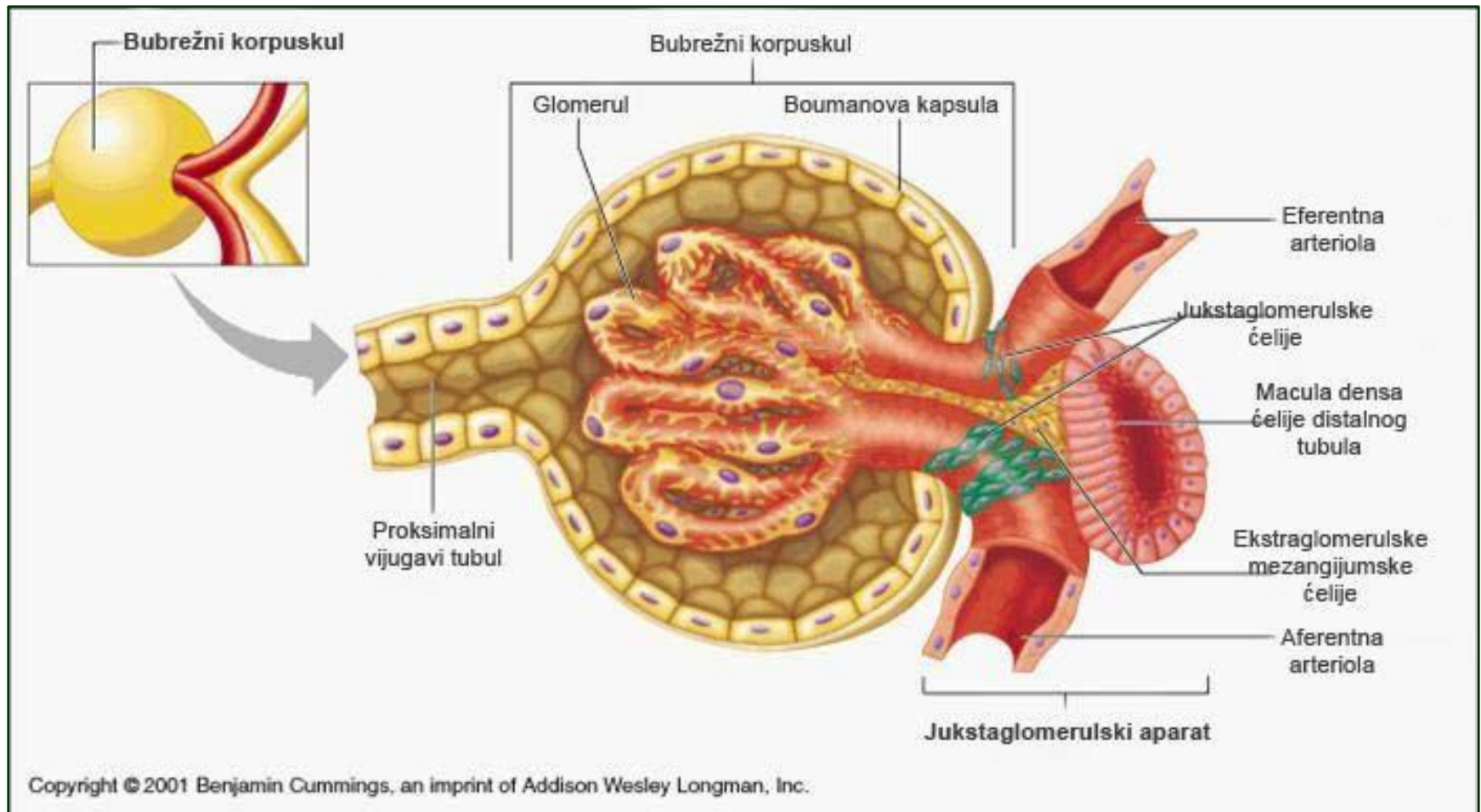
- **A thin segment of the loop of Henle**
- Single row squamous epithelium
- **Distal straight tubule (dist. thick segment HP)**
- Single row square
- **Distal convoluted tubule**
- Distal cuboid nephrocytes without brush cover



Juxtaglomerular apparatus

- The juxtaglomerular apparatus (JGA) is the common name for a group of specially differentiated cells located at the vascular pole of the renal corpuscle.
- This complex participates in the regulation of systemic blood pressure
- through the renin - angiotensin - aldosterone mechanism
- JGA consists of
 - macula densa,
 - juxtaglomerular cells,
 - extraglomerular mesangial cells

Juxtaglomerular apparatus



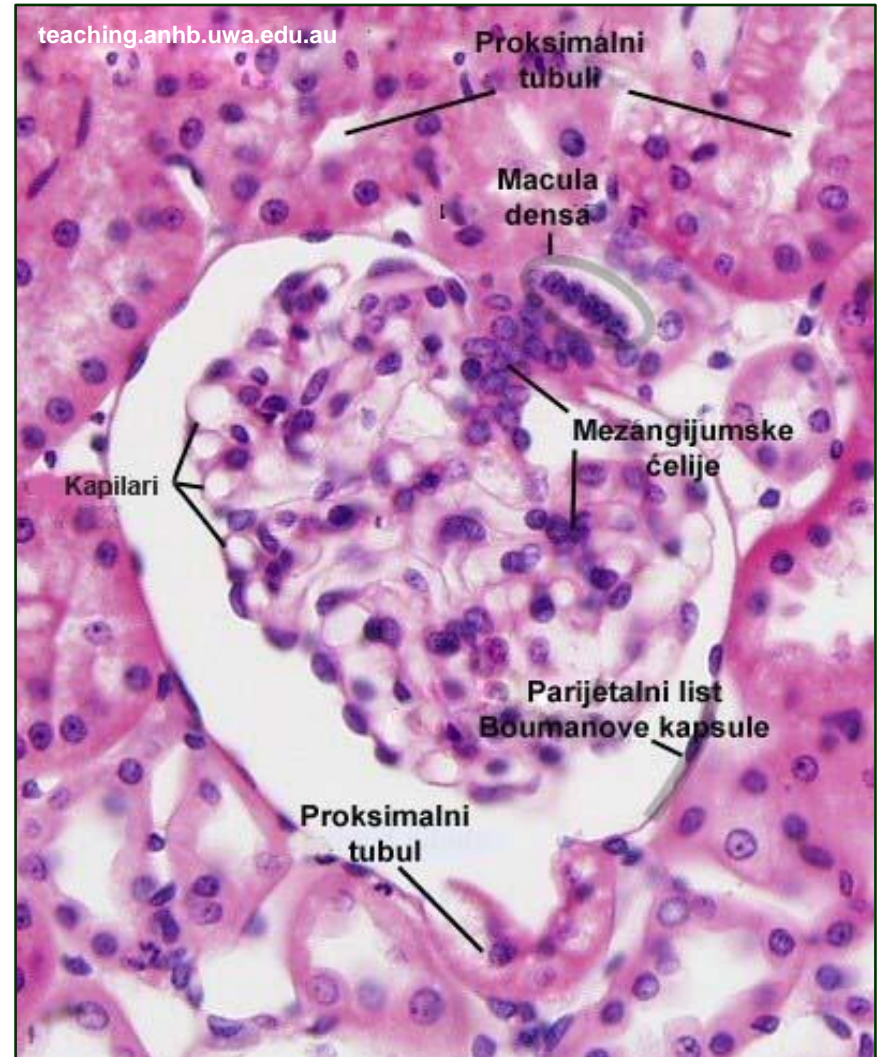
Juxtaglomerular apparatus

- **Macula densa**

- At the point of contact between the distal convoluted tubule and the supply arteriole
- Nephrocytes in the tubule are thin and tall, and the nuclei are compact - "dense stain".

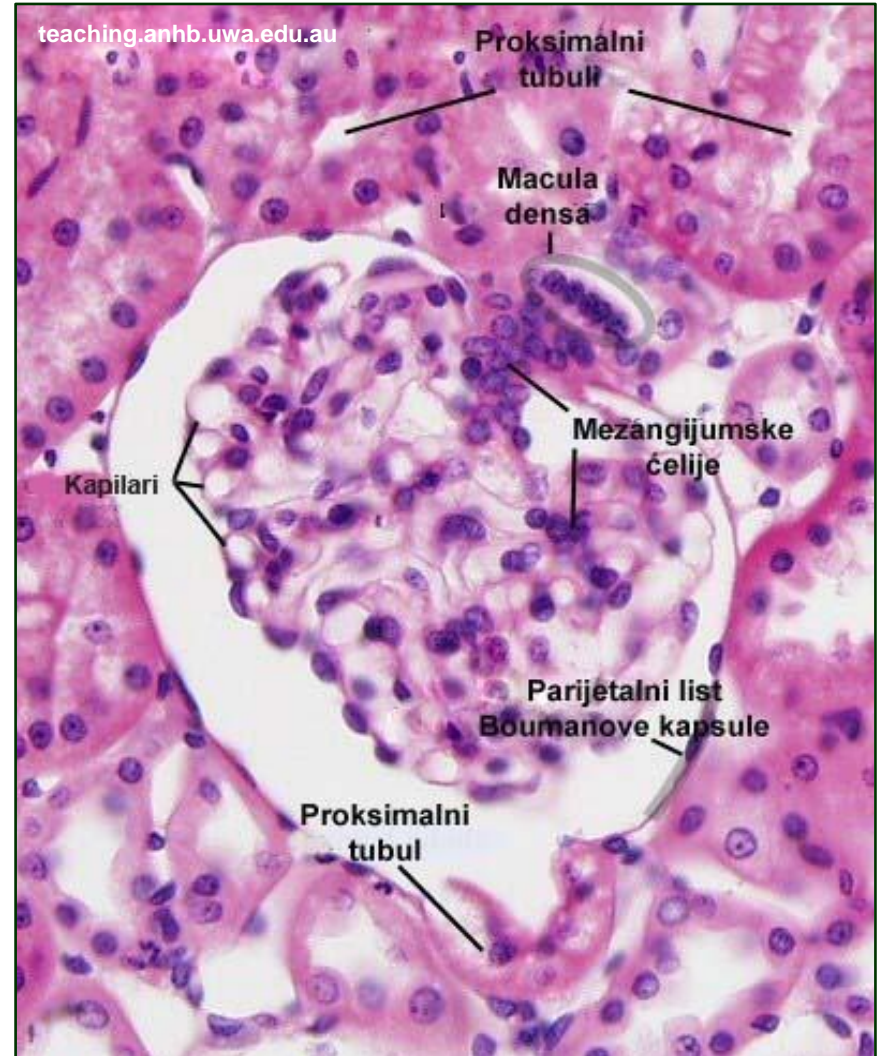
- **Juxtaglomerular cells**

- In the media of supply arterioles at the point of contact with DVT
- Modified smooth muscle cells, synthetically active - renin
- Baroreceptors respond to a drop in blood pressure by secreting renin.



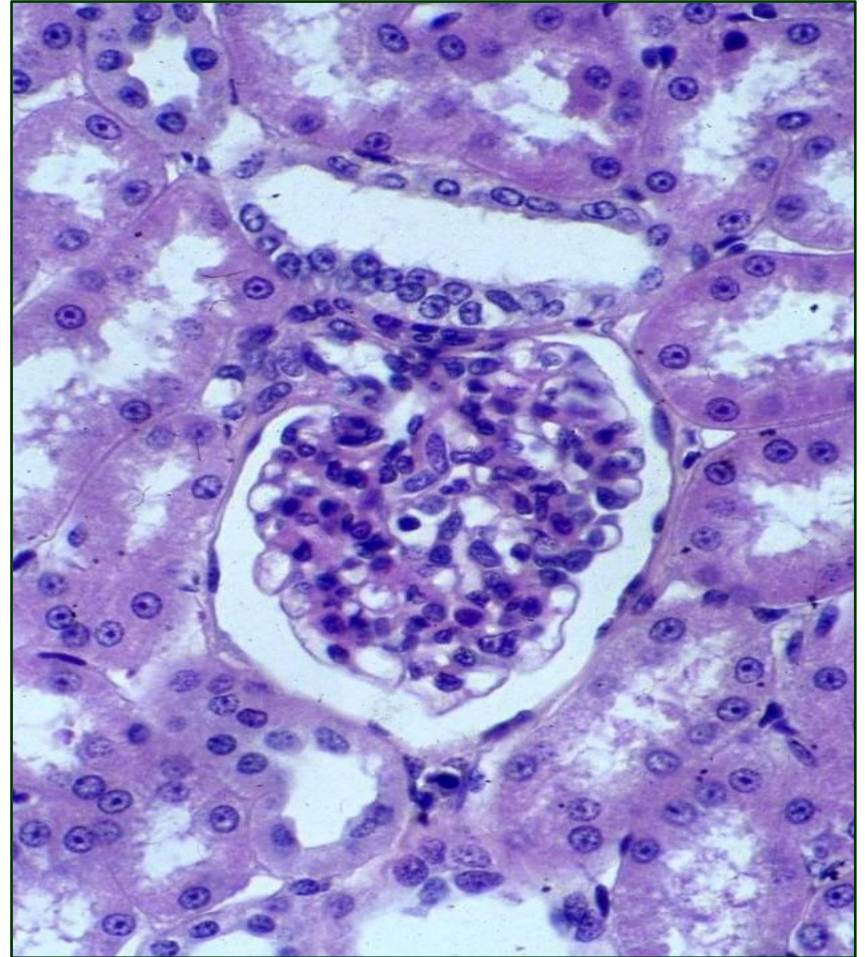
Juxtaglomerular apparatus

- **Extraglomerular mesangium cells (lacis cells)**
 - Between the macula densa supply and drainage arterioles.
 - The stellate cytotreticulum which mediates the transmission of signals from the macula densa to juxtaglomerular cells.



Juxtaglomerular apparatus

- JGA is activated when blood volume decreases and Na^+ concentration drops (baroreceptor and chemoreceptor).
- Cells of the macula densa (osmoreceptors) act on juxtaglomerular cells
- Juxtaglomerular cells synthesize renin
- Renin acts on the conversion of angiotensinogen (synthesized in the liver) to angiotensin I



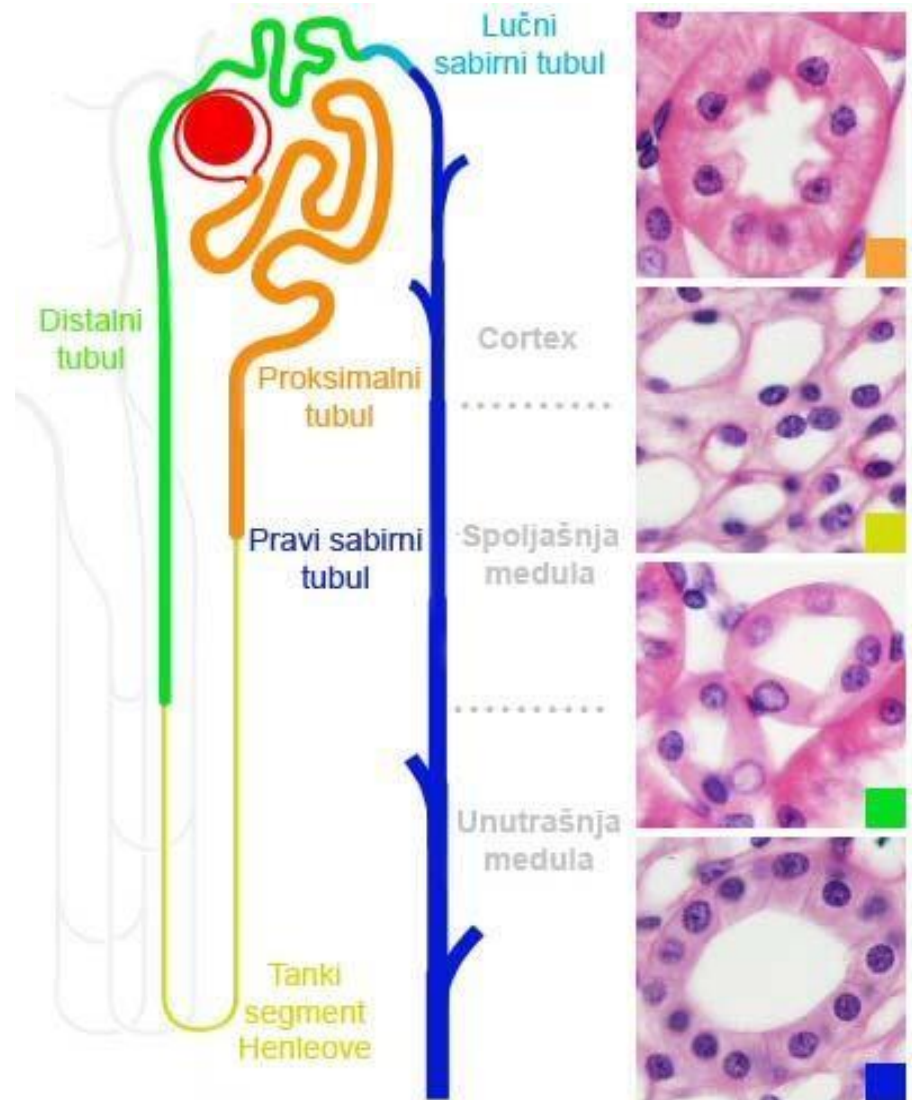
Juxtaglomerular apparatus

- Angiotensin I, under the action of ACE (angiotensin-converting enzyme), which is synthesized by the endothelium of the pulmonary capillaries, passes into angiotensin II
- Angiotensin II - vasoconstrictor; indirect action: adrenal cortex - synthesis of aldosterone - reabsorption of water in the distal tubules



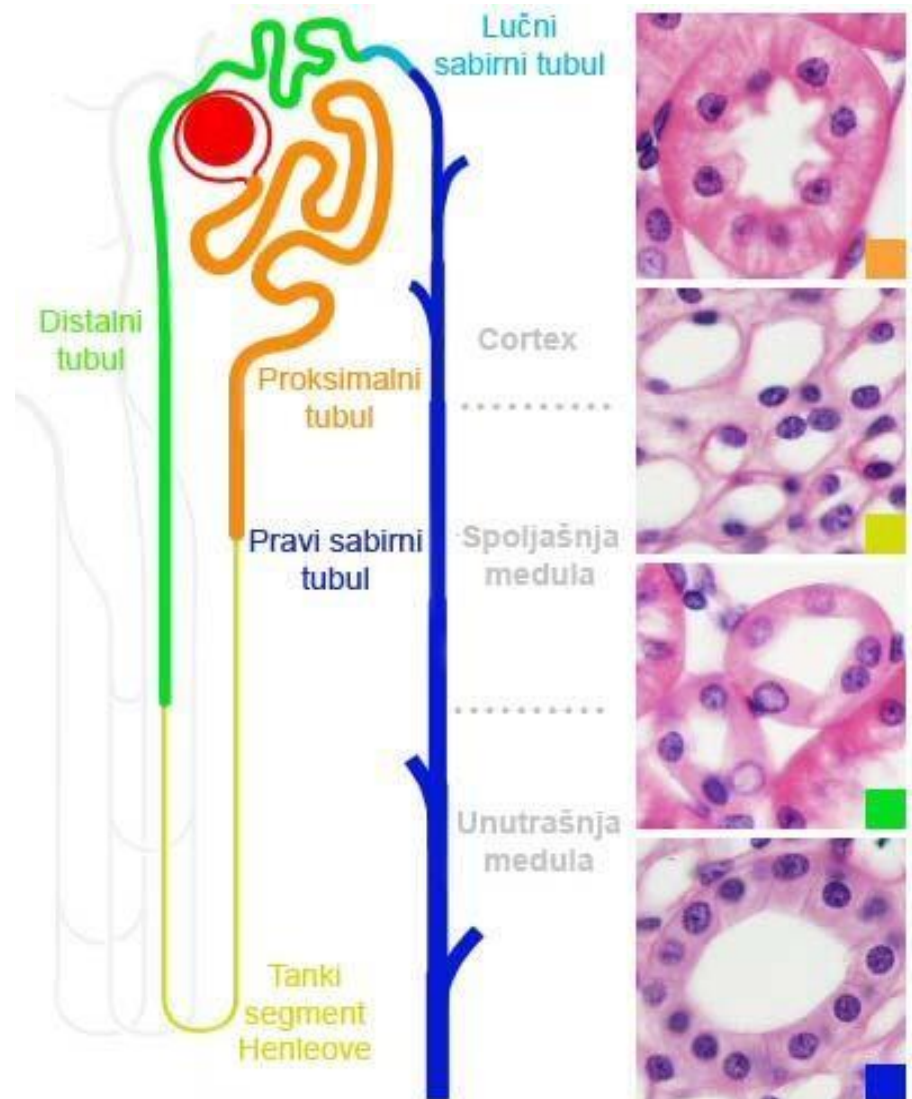
Collecting tubules and ducts

- The collecting canalicular system of the kidney consists of collecting tubules and ducts
- Their role is to transmit the part unabsorbed glomerular filtrate (definite urine) from the nephron to the small renal calyces
- In addition, in the presence of antidiuretic hormone, this system actively absorbs water and participates in the concentration of urine



Collecting tubules and ducts

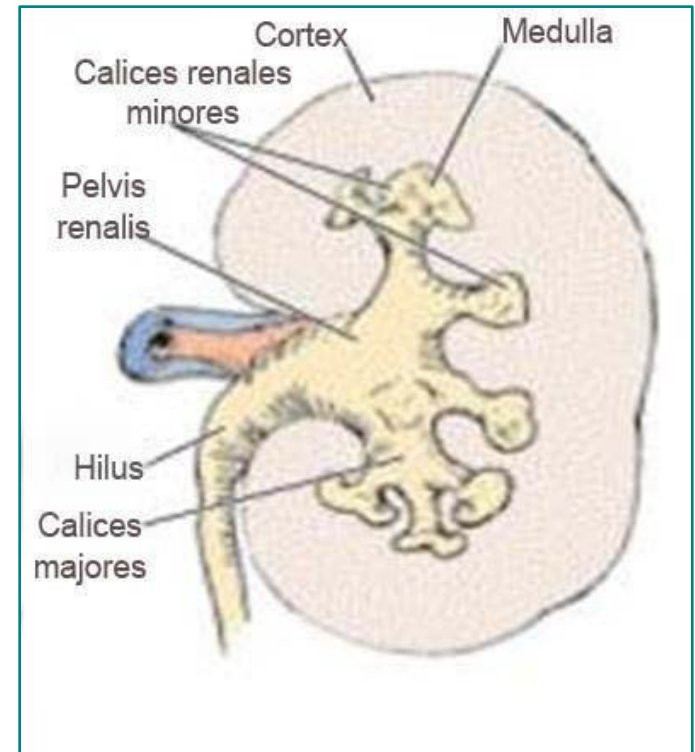
- The collecting duct system can be divided into:
 - Arc collecting tubules
 - Real collecting tubules
 - Papillary ducts



Urinary tract

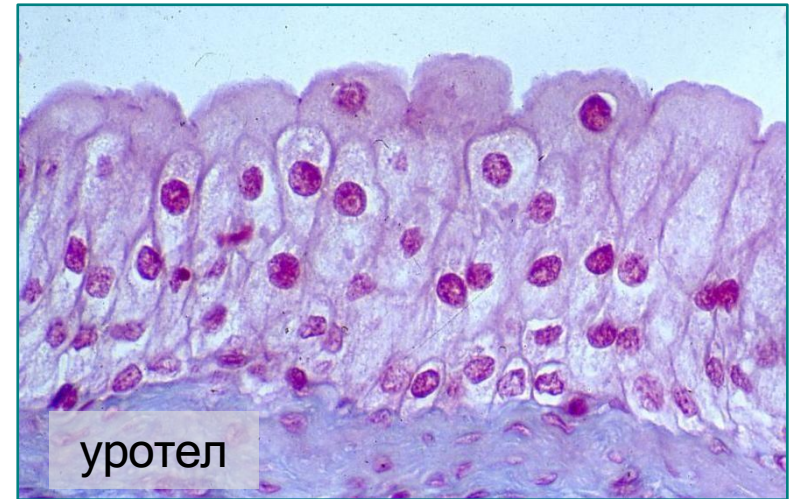
Urinary tract

- Definitely formed urine is excreted from the kidneys by papillae ducts over the lattice field of the renal papilla
- Urine from the kidneys enters the urinary tract, which have exclusively conductor role
- The urinary tract consists of:
 - Calices renales minores (small renal cups)
 - Calices renales majores (large renal cups)
 - Pelvis renalis (renal pelvis)
 - ureter
 - Vesica urinaria (urinary bladder)
 - Urethra (urinary tube)



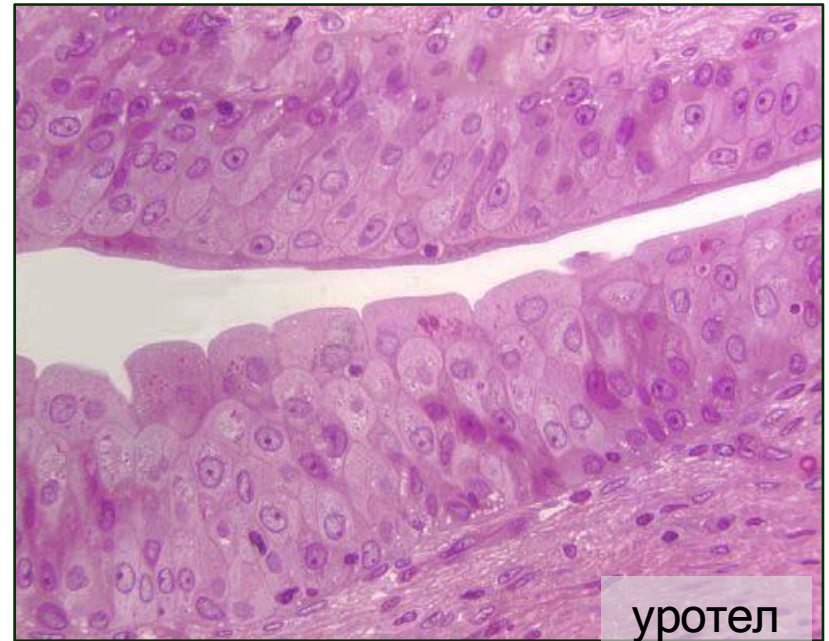Urinary tract

- All urinary tracts, except the urethra, have the same structural plan
- Their wall consists of three layers: mucosa, muscular layer and adventitia
- The mucosa of all urinary tracts, with the exception of the distal part of the urethra, is lined with transitional type epithelium (urothelium).
- Underneath the epithelium is the lamina propria
- The urothelium is impermeable to water and salts and represents an osmotic barrier between urine and tissue fluid



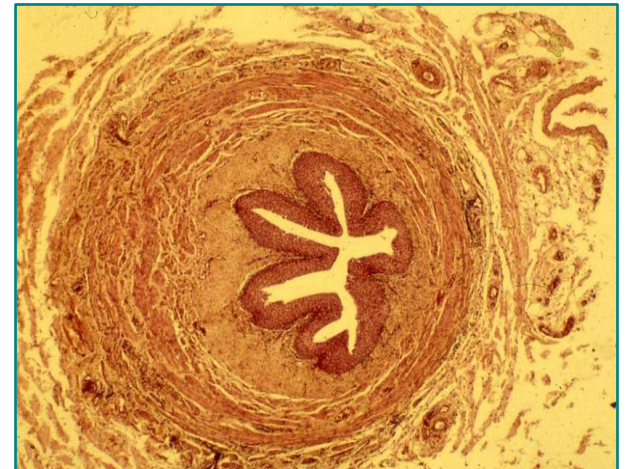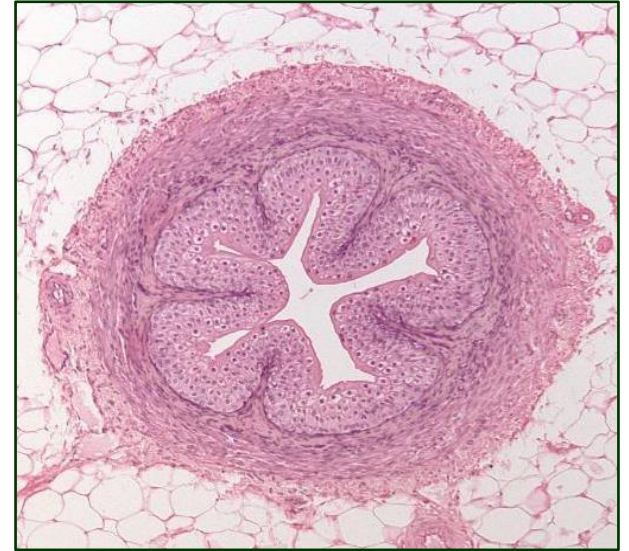
Urinary tract

- The urothelium is ideally adapted to changes in organ volume
- The muscle layer is made up of two sublayers of smooth cells:
- The inner sublayer is made up of longitudinally oriented bundles of cells
- Outer sublayer - circularly oriented
- Adventitia is a layer of loose connective tissue (adipocytes, blood and lymphatic vessels, nerves)



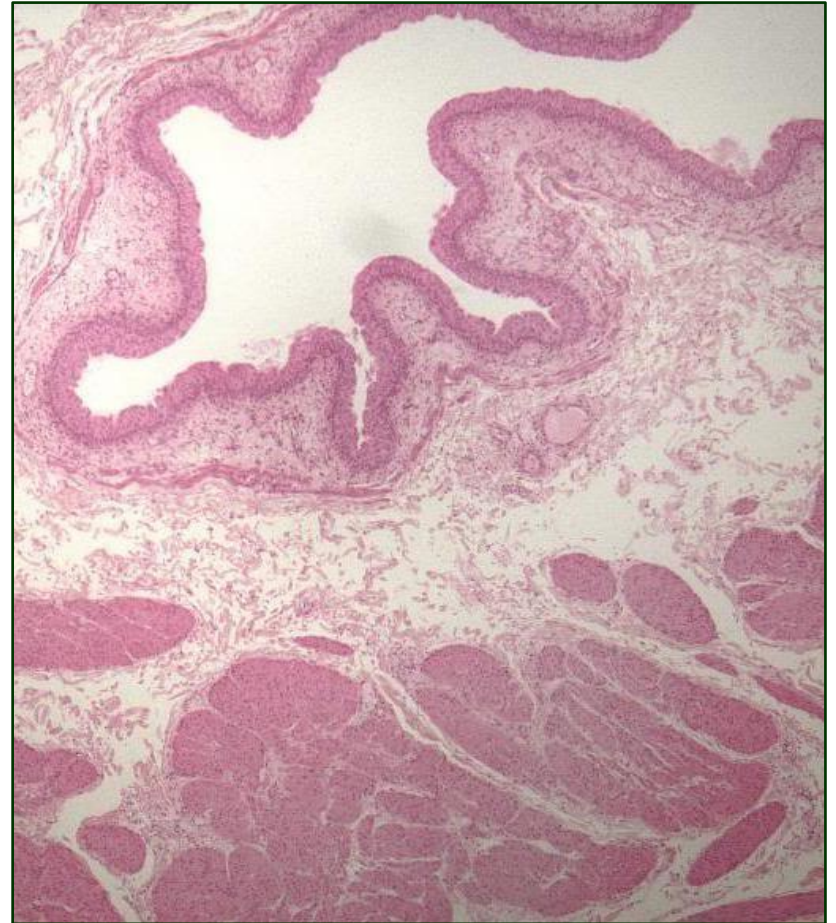
Ureter

- The urethra (ureter) is a pair of tubes
- branch about 30 cm long, caliber 4-5 mm
- Peristaltic contractions of the ureters carry urine from the renal pelvis to the bladder
- The wall of the ureter consists of:
 - Tunica mucosa
 - Lam. epithelialis
 - Lamina propria
 - Tunica muscularis
 - Internal longitudinal layer
 - Outer circular layer
 - Tunica adventitia



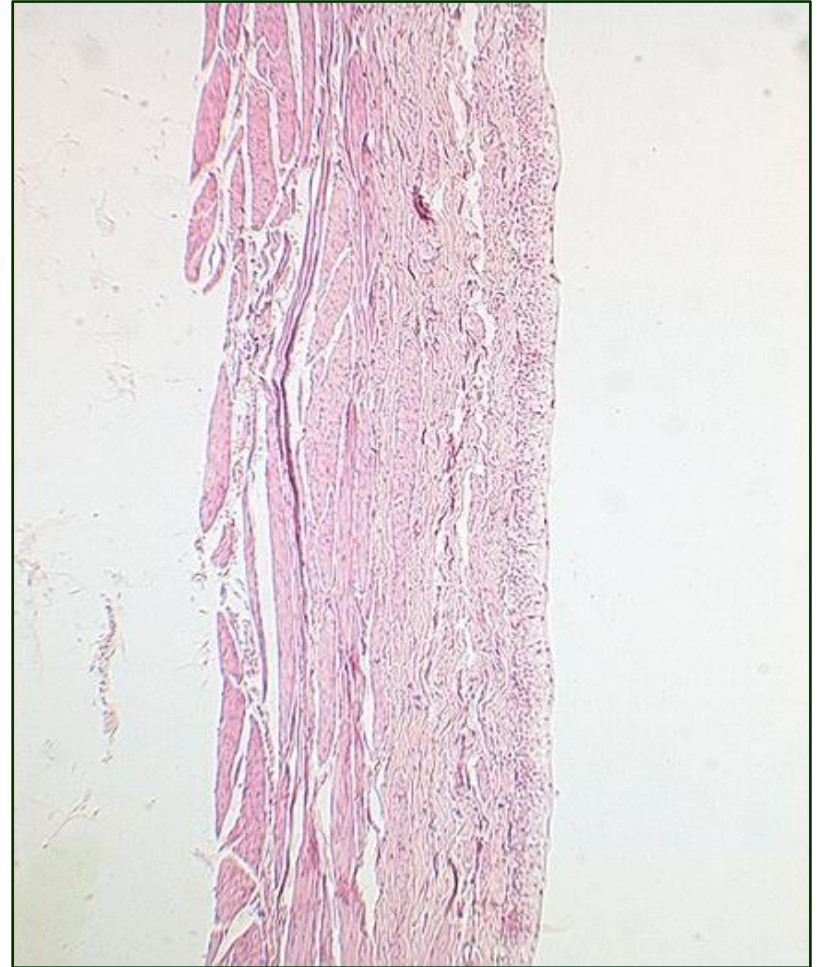Urinary bladder (vesica urinaria)

- The urinary bladder (vesica urinaria) is a stretchable bag-like organ that serves as a temporary reservoir for urine
- There are three openings in the wall - two for the ureters and one for the urethra
- The triangular part of the wall between these openings is designated as a trigonum
- The structure is similar to the ureter, but with significantly thicker muscle layer



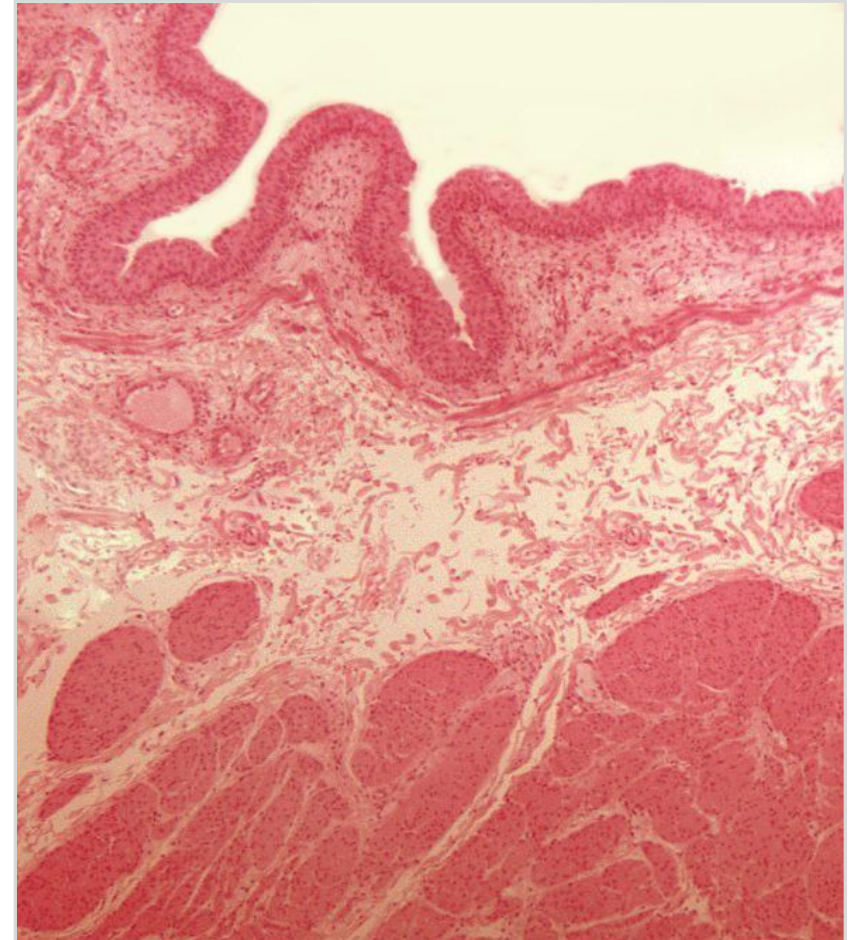
Urinary bladder (vesica urinaria)

- Between the mucous membrane and the muscle layer is the body of the submucosa
- In the area of the internal opening of the urethra, the muscular layer forms the internal sphincter of the urethra
- The largest part of the bladder is covered by the adventitia, while the serosa covers only the upper part of the organ (fundus).



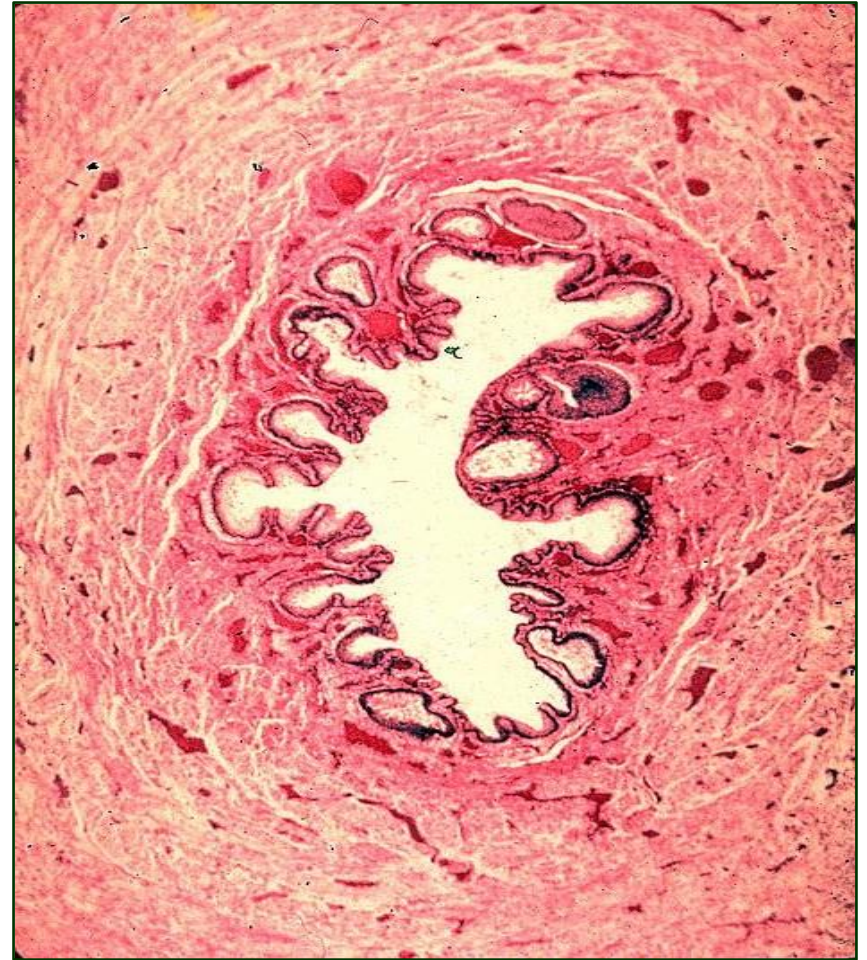
Urinary bladder (vesica urinaria)

- **Tunica mucosa**
 - Lamina epithelialis
 - Lamina propria
 - Lamina muscularis
- **Tela submucosa**
- **Tunica muscularis**
 - Inner and outer longitudinal layer
 - Central circular layer
- **Tunica adventitia**



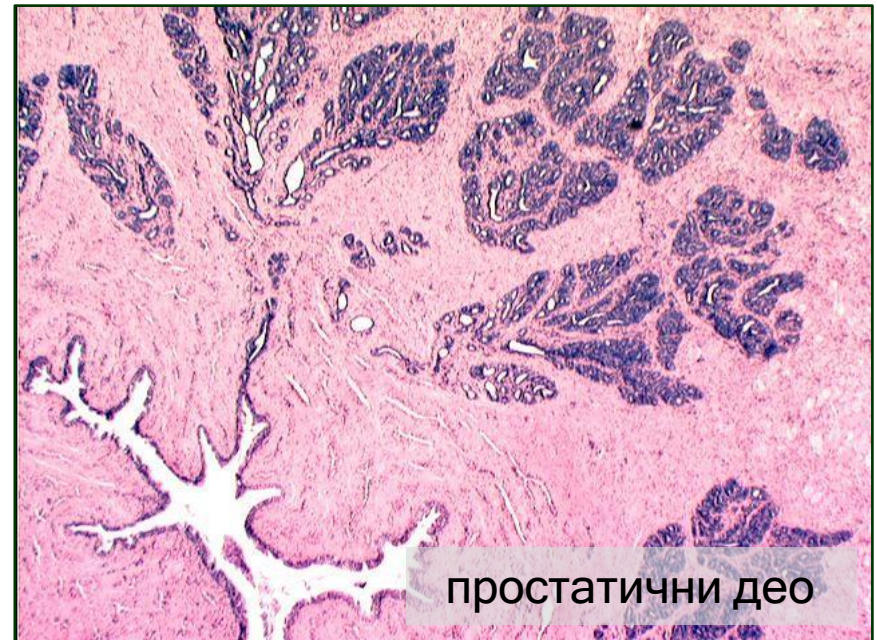Urinary tube (urethra) of a woman

- The urinary tube (urethra) drains
- urine from the bladder outside the body
- A woman's urethra is 4-5 cm long and opens in the vestibule of the vagina below the clitoris
- The central part of the urethra is surrounded by skeletal muscle fibers that build the external sphincter of the urethra (tone is controlled by the will)



Urinary tube (urethra) of a man

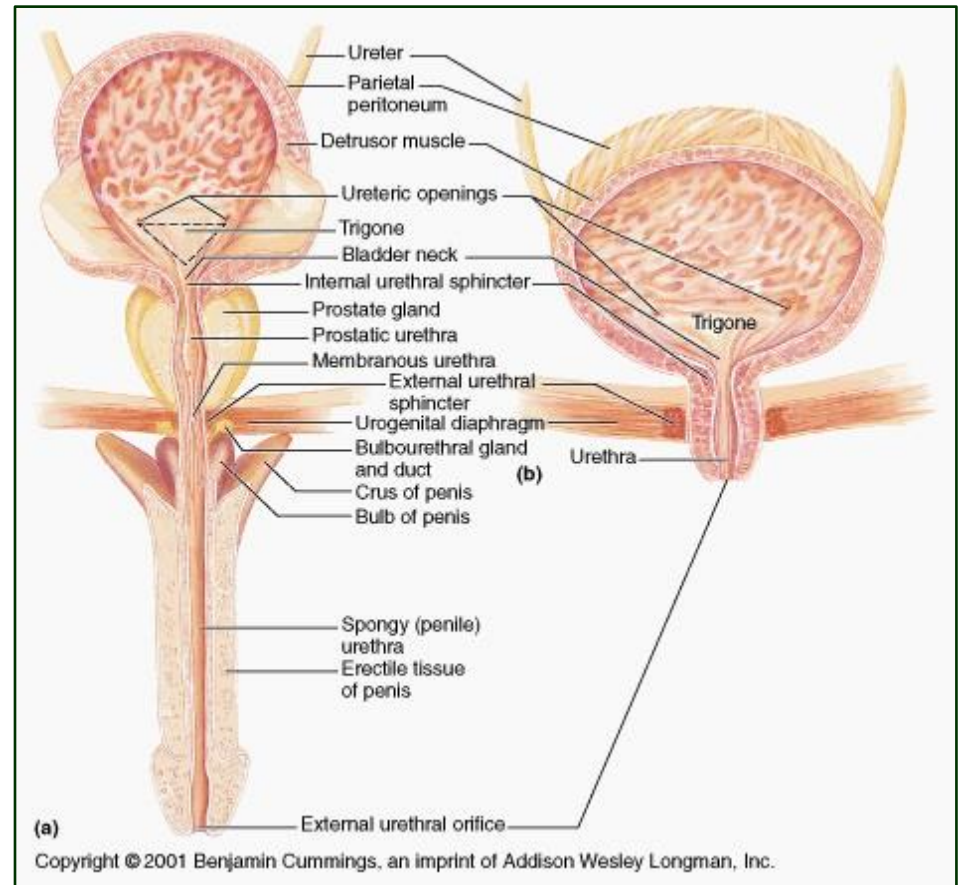
- A man's urethra is about 20 cm long
- Anatomohistologically, it is divided into three parts:
- Prostatic part
 - about 3-4 cm long and extends its entire length through the prostate
 - on the back wall there is a seminal hill, in the middle of which opens the utriculus prostaticus (blind duct of unknown significance), and to the side of it open the ejaculatory ducts



простатични део

Urinary tube (urethra) of a man

- **Membrane part**
- About 1 cm long
- Cylindrical stratified epithelium appears
- Around this part is the external sphincter of the urethra (a voluntary muscle from the skeletal muscles).



Urinary tube (urethra) of a man

- **Spongy part**

- About 15 cm long and located in the spongy body of the penis
- Lined with cylindrical stratified epithelium up to the fossa navicularis where it emerges squamous layered epithelium
- Contains mucous urethral glands (Litre's glands), whose secretion protects the epithelium from urine

